

Traumatic CSF Otorrhoea with Spontaneous Closure - A Case Report and Literature Review

Aremu Shuaib Kayode^{1*} and Fawole Olumakinde Banjo²

¹Department of ENT, Federal Teaching Hospital Ido-Ekiti, Afe Babalola University, Ado-Ekiti, Nigeria.

²Department of ENT, Federal Teaching Hospital Ido-Ekiti, Nigeria.

Authors' contributions

This work was carried out in collaboration between both authors. Author SKA designed the study, performed the statistical analysis, wrote the protocol and wrote the first draft of the manuscript. Author FOB managed the analyses of the study. Author SKA managed the literature searches. Both authors read and approved the final manuscript.

Article Information

DOI: 10.9734/AJCRMH/2018/42933

Editor(s):

(1) Dr. Khadiga Ahmed Ismail Eitris, Professor, Department of Parasitology, Faculty of Medicine, Ain Shams University, Cairo, Egypt.

Reviewers:

(1) Danijela Dragičević, University in Novi Sad, Serbia.

(2) Silke Weber, Sao Paulo State University, Brazil.

Complete Peer review History: <http://www.sciencedomain.org/review-history/25495>

Case Study

Received 27th April 2018

Accepted 11th July 2018

Published 12th July 2018

ABSTRACT

We present a 40-year-old male who was admitted via the accident and emergency unit of the hospital on account of bleeding from the left ear following the injury sustained from road traffic accident about 10 hours prior to presentation. He sustained a head injury with left cerebrospinal fluid otorrhoea. Plain radiograph revealed wavy lucencies over the temporoparietal region with soft tissue swelling and a defect in the temporal bone extending in to the tympanomastoid area. Patient was managed conservatively with spontaneous closure of the fistula and resolution of the leakage within 8 days after head injury. We report this to further emphasize the role of conservative management in CSF fistula.

Keywords: CSF otorrhoea; TM perforation; trauma.

1. INTRODUCTION

CSF rhinorrhoea and/or otorrhoea present a common management problem for the surgeon

involved in the care of cranio-facial trauma. Its recognition in patients with severe head injury is essential because as an early symptom it allows diagnosis of the fractured base of the skull,

*Corresponding author: E-mail: shuaib.aremu@gmail.com;

sometimes even better than neuroradiological methods [1] and in view of the possibility of fistula formation and meningitis [2,3]. Yet there is hardly any information in the literature on this subject from Nigeria and the subregion.

Current endoscopic techniques combined with intrathecal fluorescein dye enable most of these often difficult to diagnose, CSF leakage to be located and sealed with minimal morbidity [2-4]. Unfortunately, these techniques are not available to the vast majority of centres and personnel involved in the management of head injury in our environment.

Valtonen H et al. [5] reported 5 cases of spontaneous CSF otorrhea with tegmental defect and recommend B2-transferrin testing and combined mastoid and middle fossa approach for repair. Traumatic CSF fistulae have been described since the middle ages.

2. CASE REPORT

A 40-year-old male who was admitted via the accident and emergency unit of the hospital on account of bleeding from the left ear following injury sustained from road traffic accident about 10 hours prior to presentation.

Patient was apparently well until about 10 hours prior to presentation when he was hit from the backside by a fast moving motorcycle. He subsequently hit the face on a tarred road resulting in bruises to the face with left otorrhagia and epistaxis. Though the epistaxis had stopped prior to arrival in our centre, there was persistence of left otorrhagia. No history suggestive of ear discharge and hearing loss were present prior the incident. There was history of loss of consciousness which patient regained at a private hospital where initial first aid was administered. No bleeding from contralateral ear. No history of vertigo and no tinnitus. Also, patient had an episode of hematemesis at the referral centre.

On examination, he was found to be restless but conscious with Glasgow Coma Scale (GCS) of 14/15. He was pale, afebrile, anicteric, acyanosed and not dehydrated.

Vital signs: Pulse rate: 90 bpm. Blood Pressure: 100/70 mmHg. Respiratory rate: 24 cpm. Temperature: 36.4°C. SPO₂: 96%

The head and neck examination revealed multiple bruises on the face, laceration on the left epicanthus, periorbital ecchymosis and conjunctival haemorrhage. Also, there was swelling on the left temporoparietal region with nuchal rigidity.

Examination of the ear showed normal appearance of the pinna bilaterally. The left external auditory canal was filled with bloody effluent trickling to the concha. No tragal tenderness was present but there was fullness over the preauricular region. Endoscopic Otoscopy revealed bloody otorrhoea continued, which later turned to clear, colourless fluid with perforated tympanic membrane [Fig. 1]. No clinical signs of facial nerve palsy and no nystagmus. The presence of the CSF in the otorrhoea was ascertained by the presence of 'halo sign' when dropped on a plain white handkerchief and beta-2 transferrin.

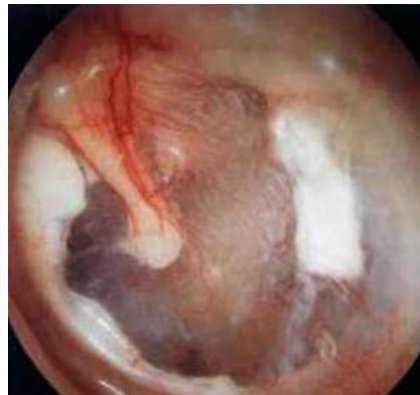

Fig. 1. Left traumatic tympanic membrane perforation

Nasal cavity has normal pyramidal shape with no septal deviation. The nasal cavity was filled with clotted blood debris, the inferior turbinates were engorged, patency slightly demonstrable bilaterally.

Oral cavity oropharyngeal examination shows mild trismus, tongue stained with altered blood, mobile in all directions, posterior pharyngeal wall could not be fully assessed.

Patient was placed in 30 degree head up position with rigid cervical collar. Intranasal Oxygen was administered. Blood samples taken for urgent PCV with electrolyte Urea and creatinine. PCV result was 17% necessitating blood transfusion.

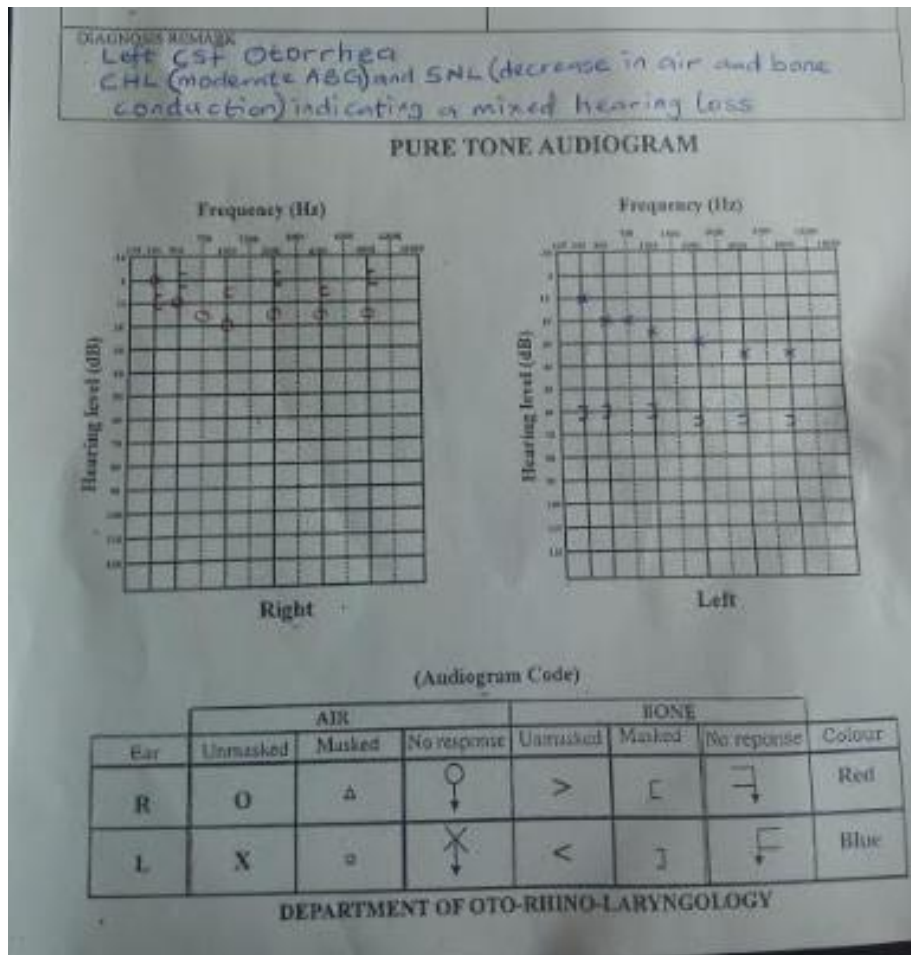


Fig. 2. PTA result-left mixed hearing loss

Cranial CT scan with bone window also requested for but due to financial reasons it was not done however, plain radiograph done revealed wavy lucencies over the temporoparietal region with soft tissue swelling.

He was placed on intravenous antibiotics and analgesics. I.M tetanus toxoid and Subcutaneous ATS were administered. Nasal decongestant was instilled 8 hourly for 48 hours. Oral chymotrypsin was also given. Patient was advised on the need to avoid excessive straining while coughing, sneezing or defecating. The left ear effluent was allowed to drain out without any form of packing or object inserted into the external auditory canal.

By the second day of admission GCS was 15/15. Patient was calmer and the rate of the effluent from the left ear has reduced and much clearer. On the fourth day, the effluent was almost clear and flow minimal as evidenced by its presence only within the canal. When patient was reviewed

on the seventh day the effluent has stopped completely. PTA (Pure Tone Audiometry) revealed moderate mixed hearing loss. [Fig. 2]

Patient was discharged to the clinic for subsequent follow up in satisfactory clinical condition.

3. DISCUSSION

Rudolf and Jan W [6] reported 4 cases of spontaneous CSF otorrhea repaired with transmatoid and micraniotomy approach. The commonest cause of CSF fistulae is trauma to the skull base. Willis was reported to be the first to record instance of CSF fistula in 1676 [7] and Walter Dandy was credited with the first successful repair of traumatic dural laceration secondary to basilar skull fracture [8]. Leakage through an enlarged labyrinthine facial nerve canal and enlarged geniculate fossa has been reported [9]. The treatment may be conservative or surgical, the goal is repair of meningeal tears

and underlying bone defects [10-13]. Head trauma accounts for 50-80% of all cases of CSF leak, and up to 16% are iatrogenic. CSF otorrhoea complicates 6% - 30% of basilar skull fractures [10,11]

Spontaneous CSF otorrhea is a rare condition and can be classified into two categories according to age. In childhood it is due to congenital deformities of labyrinths. Perilabyrinthine pathway of leak have been reported as widened fallopian canal. Hyrtl's fissure and possibility of leak via the petromastoid canal along the subarcuate artery [7]. Presentation is usually with recurrent attack of meningitis in hearing impaired child. In adult, it is almost always due to a bony and dural defect mainly in tegmen tympani. Different studies have been conducted which showed more than 20% bony dehiscence in the tegmen in selected temporal bones [8,9] This is similar in what we found in our study and in Lasisi et al study [14]. The pulsatile CSF pressure progressively drives the dura through the defects and because of one way valve system and blocking action of brain tissue, the dura cannot return back to normal position leading to progressive weakness and rupture of dura leading to spontaneous CSF leak [15].

Increased intracranial pressure, mastoiditis and age related dural weakness have been postulated as contributing factors for CSF otorrhea [16].

Diagnosis largely depends on suspicion especially in children. Identification of B2 - transferrin in sampled fluid is currently biochemical investigation of choice with high specificity [17,18]. Intrathecal Fluorescein is the most accurate method of localizing site of leak, however it is associated with complications like transverse myelitis and allergic reactions [19]. Nuclear studies using radioisotopes e.g. iodine I131, radio iodinated serum albumin (RISA), Ytterbium YB169 diethylenetriaminepenta acetic acid (DTPA), indium In 111 DTPA, technetium Tc 99m human serum albumin, and technetium Tc99 pertechnetate has been documented. Despite relative safety, they have limitations with false positive results of up to 33% [7,19-22]. Digital subtraction cisternography is useful when the conventional methods fail to identify the site of leak. Diagnostic yield may be improved by injection of metrizamide or omnipaque [20-23]. MRI does not have added advantage over CT scan, since herniating brain

tissue is non-functioning and hence does not show features of normal brain tissue¹⁸. In this case HRCT of temporal bone by using water soluble non ionic iodinated contrast medium (omnipaque) showed a well defined defect in tegmentympany with soft tissue bulging representing encephalocele. But overall systematic application of any form of cisternography in the diagnostic workup of a spontaneous CSF leak is not advocated until needed [24]. A positive B2-transferrin test justifies a surgical exploration, for the condition in life threatening and to reduce complications¹⁶. Traumatic or iatrogenic CSF leaks are known to have a higher inclination towards spontaneous healing. On the other hand, it has been shown repeatedly that spontaneous CSF leaks have a particular tendency to recur¹⁶. Meningitis has been reported in 25-50% of untreated traumatic CSF fistulas and 10% of patients in the first week after trauma with head injury [23-25]. The use of antibiotic prophylaxis is controversial and not routinely indicated [24]. Some authors believe that antibiotics should not be used in such patients as it may mask the presence of and detection of clinical features of infection. However we prefer the use of antibiotics to prevent the chances of the patient having meningitis as complication which may be difficult to manage.

Posttraumatic CSF fistulas persisting beyond 7 days, spontaneous CSF leaks with skull-base defects, increasing pneumocephalus, and meningitis are positive indications for surgical intervention [25-26].

4. CONCLUSION

cerebrospinal fluid (CSF) leakage through the ear structures is not very common but potentially life-threatening situation that requires rapid intervention. This case presented has further reiterate that conservative management plays a role in its management.

CONSENT

As per international standard or university standard, patient's consent has been collected and preserved by the authors.

ETHICAL APPROVAL

It is not applicable.

COMPETING INTERESTS

Authors have declared that no competing interests exist.

REFERENCES

1. Spangenberg P, Scherer R, Stolke D. Posttraumatic cerebrospinal rhinorrhoea. *Anesthesiol Intensive Med Not Fallmed Scmerzther.* 1997;32(2):105-108.
2. Choi D, Spann R. Traumatic cerebrospinal fluid leakage: Risk factors and the use of prophylactic antibiotics. *Br J Neurosurg.* 1996;10(6):571-575
3. Swift AC, Foy P. Advances in the management of CSF rhinorrhoea. *Hosp Moo.* 2002;63(1):28-32.
4. Marshall AH, Jones NS, Robertson N. CSF rhinorrhoea: The place of endoscopic sinus surgery. *Br J Neurosurg.* 2001; 15(1):8-12.
5. Valtonen H, Geyer C, Tarlov E, Heilman C, Poe D. Tegmental defects and cerebrospinal fluidotorrhea. *Orl. Journal of Oto-Rhino-Laryngology and Its Related Species.* 2001;63(1):46-52.
6. Rudolf K, Jan WC. Spontaneous cerebrospinal fluid otorrhea form a tegmen defect: Transmastoid repair with minicraniotomy. *Ann Otol rhinol laryngol.* 1999;108:653-658.
7. Walter D. Pneumocephalus (Intracranial Pneumatocoles or arocele) *Archieve of Surgery.* 1926;12:949-982.
8. Ignelzi RJ, Vander Ark GD. Analysis of the treatment of basilar skull fractures with and without antibiotics. *Journal of Neurosurgery.* 1975;43:721-726.
9. Chan DT, Poon WS, Chiu PW, Goh KY. How useful is glucose detection in diagnosing cerebrospinal fluid leak? The rational use of CT and Beta -2 transferrin assay in detection of cerebrospinal fluid fistula. *Asian Journal of Surgery.* 2004;27: 39-42.
10. Buchanan RJ, Brant A, Marshall LF. Traumatic cerebrospinal fluid fistulas. In: Winn HR, ed. *Youmans neurological surgery.* 5th ed. Philadelphia: W. B. Saunders Co. 2004;5265-5272.
11. Lee KJ. Highlights and pearls. In: *Essential Otolaryngology Head & Neck Surgery* 8th Edition, McGraw – Hill medical Publishing Division USA. 2003;1015-1093.
12. Gacek RR, Leipzig B. Congenital cerebrospinal otorrhea. *Ann otol rhinol laryngol.* 1979;88:358-65.
13. Ignelzi RJ, Vander Ark GD. Analysis of the treatment of basilar skull fractures with and without antibiotics. *Journal of Neurosurgery.* 1975;43:721-726.
14. Akeem OL, Mohammed AK, David OU. Spontaneous closure of traumatic CSF otorrhea following conservative Management. *Afr J Health Sci.* 2006;13: 78-80.
15. Neely JG, Neblett CR, Rose JE. Diagnosis and treatment of spontaneous cerebrospinal fluid otorrhea. *Laryngoscope.* 1982;92:609-12.
16. Ologe FE, Odebode TO. Cerebrospinal fluid (CSF) rhinorrhoea and/or otorrhea in patients with head injury. *Afi. 1. Meel. Meel.* 5(1. 2005;34:173-175.
17. Skedros DG, Cass SP, Hirsch BE, Kelly RH. B2 transferrin assay in clinical management of cerebral spinal fluid and perilymphatic fluid leaks. *Journal of otolaryngology.* 1993;22(5):341-4.
18. McGuirt WF, Stool SE. Cerebrospinal fluid fistula: The identification and management in pediatric temporal bone features. *Laryngoscope.* 1995;105(4):359-64.
19. Park JI, Strelzow VV and Friedman WH. Current management of cerebrospinal fluid rhinorrhoea. *Laryngoscope.* 1983;93:1294-1300.
20. Petrus LV, LO WW. Spontaneous CSF otorrhea caused by abnormal development of the facial nerve canal. *American Journal of Neuroradiology.* 1999;20:275-277.
21. Burton EM, Keith JW, Linden BE, Lazar RH. CSF fistula in a patient with Mondini deformity: Demonstration by CT cisternography. *American Journal of Neuro-radiology.* 1990;11:205-207.
22. May JS, Mikus JL, Matthews BL, et al. Spontaneous cerebrospinal fluid otorrhea from defects of the temporal bone: A rare entity? *American Journal of Otology.* 1995; 16:765-771.
23. Mahaley MS Jr, Odom GL. Complications following intracranial injections of fluorescein. *Journal of Neurosurgery.* 1966;25:298-299.

24. Gacek RR. Evaluation and management of temporal bone arachnoid granulation. Arch Otolaryngol Head and Neck Surgery. 1992; 118:327-32.
25. Probst C. Neurosurgical treatment of traumatic frontobasal CSF fistulae in 300 patients. Acta Neurochirugen (Wien). 1990;106:37-47.
26. Stankiewicz JA. Cerebrospinal fluid fistula and endoscopic sinus surgery. Laryngoscope. 1991;101:250-256.

© 2018 Kayode and Banjo; This is an Open Access article distributed under the terms of the Creative Commons Attribution License (<http://creativecommons.org/licenses/by/4.0>), which permits unrestricted use, distribution, and reproduction in any medium, provided the original work is properly cited.

Peer-review history:

The peer review history for this paper can be accessed here:

<http://www.sciencedomain.org/review-history/25495>