



# Hepatocurative Effect of Some Ethnomedicinal Plants on Liver Function Indices in Alloxan-Induced Diabetic Rats

Idris Aliyu Kankara <sup>a\*</sup>, Akos Noel Ibrahim <sup>a</sup> and Haruna Ade <sup>a</sup>

<sup>a</sup> Department of Science Laboratory Technology, Federal Polytechnic Kaura Namoda, Zamfara State, Nigeria.

## Authors' contributions

This work was carried out in collaboration among all authors. Author IAK designed the study, performed the statistical analysis, wrote the protocol and wrote the first draft of the manuscript. Authors ANI and HA managed the analyses of the study. Author HA managed the literature searches. All authors read and approved the final manuscript.

## Article Information

DOI: 10.9734/AJRB/2023/v12i1223

## Open Peer Review History:

This journal follows the Advanced Open Peer Review policy. Identity of the Reviewers, Editor(s) and additional Reviewers, peer review comments, different versions of the manuscript, comments of the editors, etc are available here: <https://www.sdiarticle5.com/review-history/96421>

Original Research Article

Received: 25/10/2022  
Accepted: 30/12/2022  
Published: 05/01/2023

## ABSTRACT

**Aims:** This research investigated the curative effects of *Moringa oleifera* (MO), *Treculia africana* (T.A.), and *Albizzia chevalieri* (A.C.) plant extracts on the liver function indices in Alloxan-induced diabetic rats.

**Study Design:** Albino rats were grouped into five (5) main groups MO, TA, A.C., Normal Control (N.C.), and Diabetic Control (D.C.) groups.

**Place and Duration of Study:** Department of Science Laboratory Technology, Federal Polytechnic Kaura Namoda, between May 2021 and July 2021.

**Methodology:** Diabetes mellitus was caused by a single dose intraperitoneal injection of Alloxan 150 mg/kg body weight. Liver function indices were determined using standard methods.

\*Corresponding author: E-mail: [aliyukankara@gmail.com](mailto:aliyukankara@gmail.com);

**Results:** Intraperitoneal injection of 150 mg/kg of Alloxan in the albino rats resulted in a significant ( $p < 0.05$ ) increase of Aspartate aminotransferase (AST), Alanine aminotransferase (ALT) and Alkaline phosphatase (ALP) activities, Direct and Total bilirubin while total protein concentration was significantly ( $p < 0.05$ ) decreased in the diabetic albino rats when compared with that of the non-diabetic rats (N.C.) group. Oral administration of MO, TA, and A.C. extracts to the diabetic albino rats for 21 days significantly ( $p < 0.05$ ) decreased AST, ALT, and ALP activities, direct and total bilirubin concentration. While total protein concentration was significantly ( $p < 0.05$ ) increased in the diabetes-treated groups. Histopathological studies confirmed the toxic effect of Alloxan in the liver of induced diabetic albino rats and the hepatocurative effect of the studied medicinal plants. MO (800mg/kg) demonstrated the most significant ( $p < 0.05$ ) curative effect compared to T.A. and A.C. Possible mechanism for hepatocurative of the studied medicinal plants may be due to free radical scavenging potential in the plant extracts.

**Conclusion:** In conclusion, the results of the present study demonstrate that *Moringa oleifera*, in a dose-dependent manner, has the most potent hepatocurative effect, followed by *Albizzia chevalieri*, then *Trecullia Africana* against Alloxan-induced liver damage.

**Keywords:** Diabetes; hepatocurative; ethnomedicinal plants; liver function indices.

## 1. INTRODUCTION

Ethnomedicinal plants and their phytochemical compounds have been used for treating diabetes mellitus throughout the world, especially in developing countries where access to the standard treatment of diabetes mellitus is inadequate [1]. Phytochemical compounds from ethnomedicinal plants have been used to treat various ailments for decades and have contributed massively to developing many novel therapeutic drugs for curative and preventive purposes [2]. Recent research has shown an increase in the utilization of ethnomedicinal plants and their phytochemical compounds worldwide [3]. These natural substances have had various therapeutic uses in the healthcare system from time immemorial [4]. About 80% of the world's population has accepted plants as the primary source of their healthcare system for maintaining well-being [5]. In West African countries, thousands of ethnomedicinal plants are traditionally used for managing and controlling diabetes mellitus, but only a few such plants have received scientific investigation [6].

“Diabetes mellitus is a metabolic disease characterized by elevated serum glucose levels above 200 mg/dl of fasting blood glucose level [4] and disturbances in the metabolism of carbohydrates, lipids, and proteins” [7,3]. “It occurs when the beta cell of the pancreas does not produce enough insulin (Type I Diabetes) or when the body cannot effectively utilize the insulin it produces (Type II diabetes)” [7,8]. “The World Health Organization (WHO) estimated that 422 million people worldwide with diabetes in 2014. In 2019, diabetes was the cause of direct

death of 1.5M, and 48% of all deaths due to diabetes occurred before the age of 70” [9,10,11].

Much attention has been given to studying the hyperglycemic and hyperlipidemic effects of diabetes mellitus type 2. However, little is known about the evolution of liver injury in patients with type 1 diabetes mellitus [12,13,14]. Therefore, Therefore, this research evaluated hepatocurative effect of *Moringa oleifera*, *Albizzia chevalieri* leaves, and *Trecullia Africana* on serum liver function indices and morphological changes caused by diabetes induced by Alloxan in albino rats.

## 2. MATERIALS AND METHODS

### 2.1 Collection and Identification of Plant Materials

The fresh *Moringa oleifera* (horseradish tree), *Albizzia chevalieri* leaves, and *Trecullia Africana* seeds were obtained from their natural habitat in Mal. Sani Nasiru Farm, Yankaba village, Kaura Namoda local government, Silami of Sokoto State, and Umuidi community of Anambra State, Nigeria, respectively. The samples were identified and authenticated by the Department of Science Laboratory Technology, Federal Polytechnic Kaura Namoda, Zamfara State, Nigeria, using a standard procedure, and the voucher number was deposited.

### 2.2 Preparation of Samples

“The samples were washed thoroughly to remove dust, and the drained parts were air-

dried. Next, the samples were pounded using a pestle and wooden mortar until the powder was obtained. Next, 500 g of each powdered sample was soaked in 2.5 L of distilled water and agitated intermittently for 24 hours using a platform shaker. The mixture was then filtered with filter paper (Number 1) to obtain the aqueous extract. It was then allowed to dry in an oven at 37 °C for 24 hours to obtain the crude extract. The extracts were stored in an airtight container for further work. Finally, the required doses of 200 mg, 400 mg, and 800 mg/kg body weights were obtained by reconstituting the stored extract using distilled water" [15].

### 2.3 Experimental Animals

Thirty-six (36) male albino rats weighing 100 – 200 g were used for the study. The rats were kept at the animals' house under normal environmental conditions and maintained with free access to pelletized growers' feed and access to water ad libitum. The albino rats were allowed to acclimatize for 14 days. All animal procedures were performed according to the Guide for the Care and Use of Laboratory Animals of the National Institute of Health and the guidelines of the Animal Welfare Act, 1999.

### 2.4 Experimental Design

Method of Aja et al. [4] was adopted in study with little modification. By the end of the 14 days acclimatization period, the animals were randomly assigned into five main groups of three rats. They were labeled as Normal Control (N.C.) and Diabetic Control (D.C.) *Moringa oleifera* (MO), *Trecullia Africana* (T.A.) and *Albizzia chevalieri* (A.C.). The NC group received water and feed only and served as Normal control (N.C.). Diabetes was induced in all the other groups. The DC group was not treated, and it served as Diabetic control. The MO, TA, and A.C. groups were further subdivided into three subgroups, with three albino rats in each group. They were designated MO1, MO2, MO3, TA1, TA2, TA3, and AC1, AC2, AC3, and 200, 400, and 800 mg/kg of MO, TA, and A.C. were administered, respectively. In addition, group MO received *Moringa oleifera* extract, the T.A. group received *Trecullia Africana* extract, and the A.C. group was treated with *Albizzia chevalieri* extract. The extracts were orally administered to induce diabetes in the albino rats once daily for 21 days.

### 2.5 Induction of Diabetes

"All rats, except the Normal Control Group, were intraperitoneally injected with 150 mg/kg body weight of the prepared Alloxan. After seventy-two hours of alloxan administration, the albino rats fasted overnight, and diabetes was confirmed in the rats by measuring their fasting blood glucose level with a single-touch glucometer. Rats with fasting blood glucose levels >7.0 mmol/l (126 mg/dl) were considered diabetic and included in the study" [1].

### 2.6 Collection of Blood Sample

After three weeks of treatment with the different extracts, the albino rats fasted overnight. The rats were anesthetized by placing them in a sealed cotton wool soaked in a diethyl ether inhalation jar. The albino rats were sacrificed by decapitation (at the end of 3 weeks of treatment), and blood samples were obtained and centrifuged at 4000 xg for 10 min at 40°C. The supernatant was kept at 37°C for further biochemical measurements. Fasting blood sugar and Lipid profile were then estimated.

### 2.7 Determination of Biochemical Parameters

Serum glucose level and lipid profile were determined using standard methods as previously described in [15] using the Randox kit.

### 2.8 Determination of Liver Function Indices

Alkaline phosphatase (EC. 3.1.3.1) activity was evaluated by the Para-Nitrophenyl phosphate (PNPP) method (3). Alanine aminotransferase (EC. 2.6.1.2) and aspartate aminotransferase (EC. 2.6.1.1) according to the methods [4] Serum total protein and total bilirubin as described by [5]. Assay kits used were obtained from the Randox kit.

### 2.9 Preparation of Tissue Homogenate

The liver was dissected and washed in ice-cold saline to remove the blood. 0.5g of the liver tissue was homogenized using 4.5ml of 0.4 mol/L phosphate buffer solution prepared in ice-cold saline (0.9%), and the homogenized tissue was centrifuged at 4000rpm at 40°C for 10 minutes [6].

## 2.10 Histopathological Examination

Histopathological examination of the liver was carried out using the method described by [6]. The liver was fixed in a 10% buffered formalin solution. Then, the formalin-fixed organ specimens were embedded in paraffin wax, serially sectioned (3–5  $\mu\text{m}$ ), and stained with hematoxylin and eosin. The stained tissues were observed for pathological changes using light microscopy.

## 2.11 Data Analysis

The results were presented as Mean and Standard error means (SEM), and n represents the number of animals used. The differences between means were carried out using one-way analyses of variance (ANOVA) using the statistical software SPSS version 20. The Duncan post Hoc comparison test was used to check differences between individual groups, and mean differences were considered significant when  $P < 0.05$ .

## 3. RESULTS AND DISCUSSION

The result of the hypoglycemic and hypolipidemic effects of the mentioned medicinal plants on Alloxan-induced diabetes rats was previously reported in [15].

Intraperitoneal injection of Alloxan in albino rats resulted in a significant ( $p < 0.05$ ) increase of ALP, ALT, and AST enzymes activities in the serum of the diabetic control group (DC) when compared with the non-diabetic group (NC). Also, direct and Total bilirubin concentrations were significantly ( $p < 0.05$ ) increased in the diabetic control group

compared with the non-diabetic group. At the same time, total protein concentration was decreased significantly ( $p < 0.05$ ) in the serum of the diabetic rats when compared with the non-diabetic group (Table 1).

Treatment of the diabetic groups with three different medicinal plants (MO, TA, and AC) at different doses for three weeks resulted in a significant ( $p < 0.05$ ) decrease of the elevated direct bilirubin, total bilirubin concentration, ALT, AST, and ALP enzymes activities in diabetic treated groups when compared with diabetic control (Table 1). While significant increase ( $p < 0.05$ ) in serum Total protein concentration was observed in all treated groups when compared with the diabetic control group (Table 1). The above results (Table 1) show that MO at 800mg/kg demonstrated the most significant hepatocurative effect followed by AC at 800mg/kg than TA extract in restoring the liver biomarker indices to the average level in alloxan-induced diabetic albino rats.

“The results of this study show that intraperitoneal injection of alloxan results in a significant ( $p < 0.05$ ) increase in the activities of liver enzymes in the diabetic group compared to the non-diabetic group (Table 1). Because Alloxan gets metabolized in the liver by CYP 450 2E1, oxidative pathways contribute significant production of free radicals” [9,16]. “These free radicals and other toxic metabolites cause lipid peroxidation and damage the hepatic cell membrane, causing the release of liver enzymes in circulation” [17,18,14]. Serum enzymes; (AST; aspartate aminotransaminases (AST), alanine amino transaminases (ALT), alkaline phosphatase (ALP),  $\gamma$ -glutamyltranspeptidase

**Table 1. Effect of medicinal plants on the liver function indices of diabetic albino rats**

Groups	AST(U/L)	ALT(U/L)	ALP(U/L)	T. bilirubin ( $\mu\text{mol/l}$ )	D. Bilirubin ( $\mu\text{mol/l}$ )	T. protein (g/dl)
NC	13.46 $\pm$ 1.15*	39.17 $\pm$ 0.75*	71.16 $\pm$ 2.48*	0.95 $\pm$ 0.02*	0.32 $\pm$ 0.05*	7.49 $\pm$ 0.39*
DC	46.59 $\pm$ 4.75	70.26 $\pm$ 4.72	167.27 $\pm$ 6.75	2.58 $\pm$ 0.10	1.25 $\pm$ 0.47	4.43 $\pm$ 0.49*
MO1	42.33 $\pm$ 6.11 <sup>c</sup>	42.8 $\pm$ 2.42*	112.33 $\pm$ 2.52*	1.92 $\pm$ 0.25*	0.82 $\pm$ 0.05*	5.78 $\pm$ 0.90*
MO2	32.33 $\pm$ 2.08*	38.83 $\pm$ 4.16*	111.33 $\pm$ 3.21*	1.72 $\pm$ 0.13*	0.83 $\pm$ 0.02*	6.43 $\pm$ 1.05*
MO3	25.00 $\pm$ 2.00*	29.5 $\pm$ 4.39*	98.33 $\pm$ 1.52*	1.32 $\pm$ 0.25*	0.74 $\pm$ 0.01*	7.04 $\pm$ 0.50*
TA1	47.16 $\pm$ 2.51*	57.56 $\pm$ 1.78*	120.33 $\pm$ 2.52*	2.30 $\pm$ 0.03*	0.85 $\pm$ 0.03*	6.43 $\pm$ 2.30*
TA2	39.00 $\pm$ 1.00*	49.50 $\pm$ 1.99*	116.00 $\pm$ 3.60*	1.92 $\pm$ 0.25*	0.83 $\pm$ 0.21*	6.23 $\pm$ 1.50*
TA3	37.33 $\pm$ 1.10*	42.63 $\pm$ 1.91*	117.33 $\pm$ 4.62*	1.84 $\pm$ 0.23*	0.80 $\pm$ 0.12*	6.19 $\pm$ 2.40*
AC1	48.33 $\pm$ 0.02*	63.06 $\pm$ 2.50*	142.67 $\pm$ 3.33*	2.11 $\pm$ 0.02*	1.10 $\pm$ 0.05*	5.69 $\pm$ 0.49*
AC2	40.83 $\pm$ 1.89*	56.13 $\pm$ 3.06*	147.00 $\pm$ 8.00*	2.32 $\pm$ 0.05*	1.30 $\pm$ 0.30*	5.89 $\pm$ 0.57*
AC3	38.96 $\pm$ 1.40*	47.00 $\pm$ 1.41*	134.33 $\pm$ 4.04*	2.00 $\pm$ 0.98*	0.90 $\pm$ 0.60*	5.99 $\pm$ 0.89*

*Ethnomedicinal plants: Significant from normal control, \* P < 0.05*

*Mean  $\pm$  S.E.M = Mean values  $\pm$  Standard error of means of three experiments*

## Histology

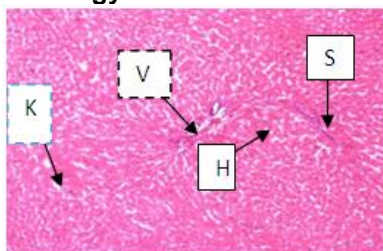


Plate 1: Photomicrograph (x 400) Liver of nondiabetic control rats (NC) showing normal-appearing of hepatocytes (H), vein (V), sinusoids (S), and Kupffer cells (K)

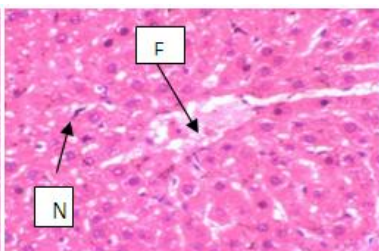


Plate 2: Photomicrograph (x 400) Liver of diabetic rat showing sinusoidal enlargement and liver fatty degeneration. The cells were sequestration and degenerated with decreased in number of nuclei

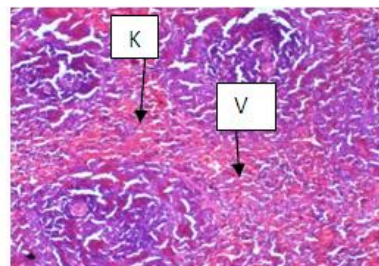


Plate 3: Photomicrograph (x 400) Liver of diabetic rat treated with *Moringa oleifera* showed Kupffer cells, non-distorted central vein with sinusoid.

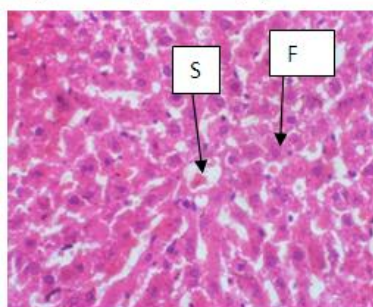


Plate 4: Photomicrograph (x 400) Liver of diabetic rat treated with *Treculia africana* showing sinusoidal enlargement and fatty vacuoles

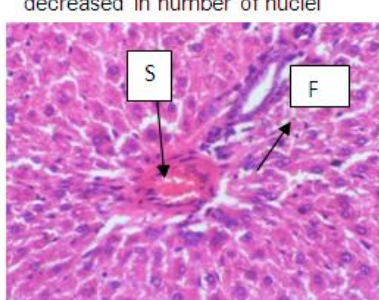


Plate 5: Photomicrograph (x 400) Liver of diabetic rat treated with *Albizzia chaliveiri* showing sinusoidal enlargement and liver fatty degeneration

(GGT) and non-enzymes (Total protein, bilirubin, and albumin) of liver biomarkers are the most common sensitive biochemical tools use for the assessment of the hepatocellular injury [3,19]. Significant increases in aminotransferases, particularly ALT, indicate hepatocellular injury, while the persistent elevation of ALP activity reflects cholestasis- hepatobiliary damage [20]. This finding agreed with [12, 21] and [3], who reported that diabetic patients were at greater risk of developing biochemical alterations in hepatic enzymes. This work also followed the findings of [22], who reported that the levels of liver enzymes were significantly ( $p < 0.05$ ) elevated among diabetic albino rats compared with non-diabetic rats.

Oral administration of *Moringa oleifera* (MO), *Trecullia Africana* (TA), and *Albizzia chevalieri* to the Alloxan-induced diabetic rats showed a significant ( $P < 0.05$ ) decreased the activities of liver enzymes; AST, ALT, and ALP when compared with diabetic control (Table 1) indicating the protection of structural integrity of hepatocellular membrane or regeneration of damaged liver cells. The findings were in line

with those reported by [21], who observed a significant decrease in liver biomarker enzyme activities in Alloxan-induced diabetics treated with *Mollugo cerviana* extract. Also, [3] reported a significant decrease in liver enzyme activities in Alloxan-induced diabetic albino rats treated with Rutin.

In addition, histological changes such as sinusoidal enlargement, fatty degeneration in hepatocytes (steatosis), cell sequestration, and degeneration with decreased nuclei were observed in an alloxan-induced diabetic group. However, MO, AC, and TA extract significantly ameliorate these histological changes, thus demonstrating their hepatocurative effect.

## 4. CONCLUSION

In conclusion, the results of the present study demonstrate that *Moringa oleifera*, in a dose-dependent manner, has the most potent hepatocurative effect, followed by *Albizzia chevalieri*, then *Trecullia Africana* against Alloxan-induced liver damage.

## ACKNOWLEDGEMENTS

This research was funded by Tertiary Education Trust Fund (TETFund) grant under Institution Based Research (IBR).

## COMPETING INTERESTS

Authors have declared that no competing interests exist.

## REFERENCES

1. Alope C, Nwachukwu N, Ugwuja EI, Nwachi E, Obasi I, Oga O. Effects of anthoxylum zanthoxyloides leaves on blood glucose, lipid profile and some liver enzymes in alloxan induced diabetic rats. International Journal of Science and Nature. 2012;3(3):497-501.
2. Yakubu O, Imo C, Shaibu C, Akighir J, Ameh AD. Effects of ethanolic leaf and stem-bark extracts of adansonia digitata in alloxan-induced diabetic wistar rats. Journal of Pharmacology and Toxicology. 2020;15(1):1-7.
3. Tanko Y, Jimoh A, Sulaiman I, Mohammed K, Salisu A, Yusuf R, Musa S. The effect of rutin on lipid profile and liver function enzymes on alloxan induced hyperglycaemic wistar rats. Bayero Journal of Pure and Applied Sciences. 2017;10(1):201-214.
4. Aja P, Igwenyi I, Okechukwu P, Orji O, Alum E. Evaluation of anti-diabetic effect and liver function indices of ethanolic extracts of moringa oleifera and *Cajanus cajan* leaves in alloxan induced diabetic albino rats. Global Veterinaria. 2015;14(3):439-447.
5. Zauro AR, Amali M, Aminu C, Bandi I, Anne OM. Review of toxic effects of medicinal plants found in Nigeria. Australian Journal of Science and Technology. 2018;2(2):99-107.
6. Masharani U, German M. Pancreatic hormones and diabetes mellitus. In Gardner D, Shoback D, Greenspan's Basic and Clinical Endocrinology (9 Ed., pp. 205-12). New York.: McGraw Hill Medical; 2011.
7. Kankara IA, Gayus AP, Aliyu M. Hypoglycaemic and hypolipidemic effects of *Treculia africana* aqueous leaves extract in alloxan induced diabetic rats. Asian Journal of Biochemistry, Genetics and Molecular Biology. 2018;1(1):1-9.
8. Singh N, Kesharwani R, Tiwar A, Patel D. A review on diabetes mellitus. The Pharma Innovation Journal. 2016;5(7):36-40.
9. WHO WH. Diabetes mellitus report of a WHO study Group. Geneva: WHO; 2022.
10. Kind R, King E. Determination of alkaline phosphatase activity by colorimetric method. J. Clin. Path. Journal Clinical Pathology. 1954;1-10.
11. Reitman S, Frankel SA. Colorimetric method for the determination of serum glutamic oxaloacetic and glutamic pyruvic transaminase. 1957;25(59).
12. Lucchesi A, Cassettari L, Spadella C. Alloxan-induced diabetes causes morphological and ultrastructural changes in rat liver that resemble the natural history of chronic fatty liver disease in humans. Journal of Diabetic Research. 2015;1-11.
13. Mahe A, Muhammad Y, Ibrahim AM, Adam I, Atiku M, AA I. *In vivo* and *in vitro* toxicity studies of crude and partially purified leaf extracts of *Jatropha curcas* in wistar albino rats. Journal of Pharmaceutical Research International. 2017;20(2):1-16.
14. Markkas N, Govindharajulu M. Protective effect of Mollugo cerviana extract on liver markers in alloxan induced diabetic rats. The Journal of Phytopharmacology. 2018;1:1-4.
15. Kankara IA, Ibrahim AN, Ade H. Comparative analysis of the hypoglycaemic and hypolipidemic effects of aqueous extract of some ethno medicinal plants in alloxan induced diabetic rats. Asian Journal of Research in Biochemistry. 2021;9(2):40-48.
16. Hodgson E. A Textbook of Modern Toxicology. Canada: John Wiley & Sons, Inc; 2004.
17. Tietz NW. Fundamental of Clinical Chemistry. W. B. Saunders Company Philadelphia; 1976.
18. Adetutu A, Olorunnisola S. Hepatoprotective Potential of some local medicinal plants against 2-acetylaminoflourene-induced damage in rat. Journal of Toxicology. 2013;1-5.
19. Kandur S, Goyal R. Beneficial effects of *Zingiber Officinale* roscoe on fructose induced hyperlipidemia & hyperinsulinemia in rats. Indian J. Exp. Biol. 2014;3(3):1161-64.
20. Atangwho I, Ebong P, Egbung E, Eteng M, Eyong E. Effect of *Vernonia amygdalina* Del. on liver function in alloxan-induced hyperglycaemic rats. Journal of Pharmacy and Bioresources. 2007;4(1):25-31.



21. Kankara I, Abdullahi I, Gayus A. Ethnomedicinal plants: A source of phytochemical compounds against snake venom PLA2s activity. *Journal of Pharmacognosy and Phytochemistry*. 2020;9(2):1270-1275.
22. Ayoade A, Oluwole O, Babara T. Kidney and liver function parameters in alloxan-induced diabetic rats treated with aloe barbadensis juice extract. *Sierra Leone Journal of Biomedical Research*. 2009; 1(1):33-37.

© 2023 Kankara et al.; This is an Open Access article distributed under the terms of the Creative Commons Attribution License (<http://creativecommons.org/licenses/by/4.0>), which permits unrestricted use, distribution, and reproduction in any medium, provided the original work is properly cited.

*Peer-review history:*

*The peer review history for this paper can be accessed here:*  
<https://www.sdiarticle5.com/review-history/96421>