

Efficacy of Double Pedicle Graft with and without PRGF in Treating CI I and CI II Gingival Recessions

Nader Abolfazli¹ • Afsoon Asadollahi^{2*} • Masoumeh Faramarzi³ • Fariba Saleh Saber⁴

¹Associate Professor, Dental and Periodontal Research Center, Department of Periodontics, Faculty of Dentistry, Tabriz University of Medical Sciences, Tabriz, Iran

² Postgraduate Student, Department of Oral Medicine, Faculty of Dentistry, Tabriz University of Medical Sciences, Tabriz, Iran

³Associate Professor, Department of Periodontics, Faculty of Dentistry, Tabriz University of Medical Sciences, Tabriz, Iran

⁴Associate Professor, Department of Prosthodontics, Faculty of Dentistry, Tabriz University of Medical Sciences, Tabriz, Iran

*Corresponding Author; E-mail: afsoon.asadollahi@gmail.com

Received: 2 June 2015; Accepted: 5 July 2015

J Periodontol Implant Dent 2015;7(2):44–49 | doi: 10.15171/jpid.2015.009

This article is available from: <http://dentistry.tbzmed.ac.ir/jpid>

© 2015 The Authors; Tabriz University of Medical Sciences

This is an Open Access article distributed under the terms of the Creative Commons Attribution License (<http://creativecommons.org/licenses/by/3.0>), which permits unrestricted use, distribution, and reproduction in any medium, provided the original work is properly cited.

Abstract

Background and aims. The aim of this study was to evaluate the effect of double pedicle graft (DPG) with and without plasma rich in growth factor (PRGF) in the treatment of Miller's CI I and II gingival recessions.

Materials and methods. Thirty-two bilateral buccal gingival Miller's CI I and II recessions were selected. Sixteen of the recessions were treated with DPG and PRGF (test group). The remaining sixteen recessions were treated with DPG (control group). The clinical parameters, including clinical probing depth (CPD), clinical attachment level (CAL), recession depth (RD), recession width (RW) and keratinized gingiva width (KGW), were measured at baseline and 1, 3 and 6 months later. Data were analyzed with paired t-test.

Results. After 6 months, both groups exhibited a significant improvement in all the criteria mentioned above. However, none of the groups showed significant differences in pocket depths after 6 months. At the end of the study there were significant improvements in recession depths and widths and clinical attachment levels and keratinized gingiva width between test and control groups

Conclusion. The method using DPG+PRGF resulted in more favorable clinical outcomes than only DPG.

Key words: Recession, double papilla graft, PRGF.

Introduction

Gingival recession is defined as the displacement of the gingival margin apical to the cementoenamel junction area, resulting in denuding of the root

surface.^{1,2} A prevalence rate of 20–100% has been reported for gingival recession in the adult population.^{3,4} Some of the complications of gingival recession are esthetic problems, tooth hypersensitivity, denuding of root surfaces, tooth susceptibility to root

surface caries, cervical abrasion and changes in the anatomy of the area, making oral hygiene procedures ineffective.⁵

Various surgical procedures are used to correct gingival recession. In general, plastic periodontal surgical procedures used to correct gingival recession can be divided into three categories:^{5,6} 1) free grafts; 2) guided tissue regeneration; and 3) pedicle grafts, which in turn are divided into rotational flaps and advanced flaps.^{6,7} The first group includes laterally positioned flap^{8,9} and double papilla flap¹⁰ and the second group includes coronally advanced flap¹¹ and semilunar flap.¹²

Based on the conclusion made by the World Workshop of Periodontics, combined techniques can be more useful and the most effective treatment modality at present is the connective tissue graft beneath the pedicle flaps, with a root coverage rate of 2.5–98% (mean=38.9%) and a complete root coverage rate of 20–89%.¹³ However, one of the disadvantages of this technique is the need for an additional surgical site to harvest connective tissue which is mainly harvested from the palate and is associated with more pain and discomfort for the patient.¹⁴

Of all the pedicle graft techniques, double papilla technique is a useful one, which was introduced by Ross and Cohen in 1968 in order to create a sufficient amount of keratinized gingiva or tooth root coverage for one tooth or several teeth adjacent to each other on the condition that the interdental papilla has adequate mesiodistal dimension.¹⁵ The chief disadvantages of this technique in its use to cover denuded root surfaces are: 1) absence of adequate mesiodistal dimension of interdental papilla; and 2) dehiscence of the two mesial and distal flaps on the avascular surface of the roots.¹⁶ In 1994 Harris used connective tissue in association with double papilla to solve the problem of dehiscence of mesial and distal flaps and achieved good results.¹⁸ The disadvantage of this technique is the creation of an additional wound in the patient's palate to harvest a graft.¹⁷ Various cellular and growth factors are involved in the wound healing processes during periodontal surgeries.¹⁸ After the surgical procedures the platelets involved in blood clot formation release a number of growth factors that play a role in cell division and differentiation and as a result, in healing and tissue regeneration.¹⁹ Therefore, these growth factors can be used to accelerate tissue healing procedures. In this context, recently platelets rich in growth factors or PRGF, which are in fact concentrated suspensions of growth factors, are used to promote periodontal tissue healing and regeneration

processes. PRGF is an autologous source for growth factors, including platelet-derived growth factors and β -converting growth factors, etc.^{20,21}

Some studies have been carried out to find an alternative for connective tissue grafts. Recent studies have shown the effect of PRP and PRGF on facilitation and improvement of soft tissue repair procedures.

The aim of the present study was to evaluate the effect of PRGF on improving the DPG repair procedure and the outcomes of the clinical procedures in the treatment of Miller's CI I and II gingival recessions.

Materials and Methods

This study was designed as a randomized, blind, split-mouth trial. It was conducted between Nov 1, 2012 and July 10, 2015 in the Department of Periodontics of the Tabriz Faculty of Dentistry.

Sixteen patients were evaluated, each with two similar bilateral lesions on anterior or premolar teeth. The subjects were selected from those referring for treatment to the Department of Periodontics, Tabriz Faculty of Dentistry, based on inclusion criteria as follows: presence of at least two Miller's CI I and II gingival recessions in the oral cavity, absence of any systemic conditions affecting the periodontium, a plaque index of <10%, presence of thick and wide interdental papilla mesial and distal to the defect (thick and wide papilla was defined as follows: the sum of the mesiodistal widths of two mesial and distal papillae at least 2 mm greater than the mesiodistal width of the recession at the most coronal part), signing of an informed consent form, absence of pregnancy, absence of root surface caries or restorations in the test and control teeth, no history of any root coverage surgical procedures in the test and control teeth, no smoking, absence of strong muscular adhesions and frenal pull.

In the control group, only double pedicle graft was used; however, in the test group, double pedicle graft was used in association with PRGF.

Preoperative Stage

All the patients underwent a careful periodontal examination. Preoperative preparation included accurate oral hygienic instructions, scaling and root planing, preparation of stone casts and if necessary, occlusal adjustment.

Clinical measurements consisted of clinical probing depth (CPD), clinical attachment level (CAL), recession depth (RD), recession width (RW), keratinized gingiva width (KGW) with the use of a UNC

probe by a periodontist other than the periodontist carrying out the surgical operations, who was blinded to the study groups. All the measurements were rounded up to 0.5 mm. The lesion sites underwent photography.

PRGF Preparation

The preparation of PRGF was performed immediately before surgery as described by Anitua.¹⁸ Prior to surgery, 10 mL of venous blood were collected from the subjects. The blood was kept in 5-mL tubes with 3.8% trisodium citrate as an anticoagulant. The tubes were centrifuged at 1,800 rpm for 8 minutes at room temperature (PRGF System II, BTI, Vitoria-Gasteiz, Spain). As a result of centrifugation, the blood was compartmentalized into the following four components.

1. Plasma poor in growth factors (PPGFs) in the upper portion of the tube and corresponding to a volume of 0.5 mL.
2. Plasma with growth factors (PGFs) comprising approximately 0.5 mL of the total volume.
3. PRGF (0.5 mL) located immediately above the red blood cell fraction in the tube.
4. Red blood cell concentrate.

The PPGF located in the upper part of the plasma in the tube was eliminated with 500- μ L pipettes. PPGF has the lowest quantity of platelets in the plasma. The functional fraction is usually 0.5 mL of PRGF located immediately above the red blood cell fraction. The PRGF was separated with 500- μ L pipettes and transported to an independent tube. Next, the PRGF was activated using 50 μ L of 10% calcium chloride. The mixture of PRGF and calcium chloride was left at room temperature for 10 min until a consistent and easy-to-handle gelatinous layer had formed.

Surgical Procedure

All the patients were treated by the same surgeon. The exposed root surfaces were scaled and planed with hand and ultrasonic instruments. After local anesthesia with 2% lidocaine + epinephrine at a concentration of 1:80,000, a #15 surgical blade was used to freshen the gingival margins of the adjacent denuded root surfaces with a v-shaped incision. Then a horizontal incision was used along the CEJ up to 0.5 mm from the gingival margin of the adjacent teeth, from which the vertical incisions were extended beyond the MGJ. A sharp dissection procedure was used to prepare two mesial and distal partial-thickness pedicle grafts. Cutback and periosteal incisions were used to provide for coronal and lateral

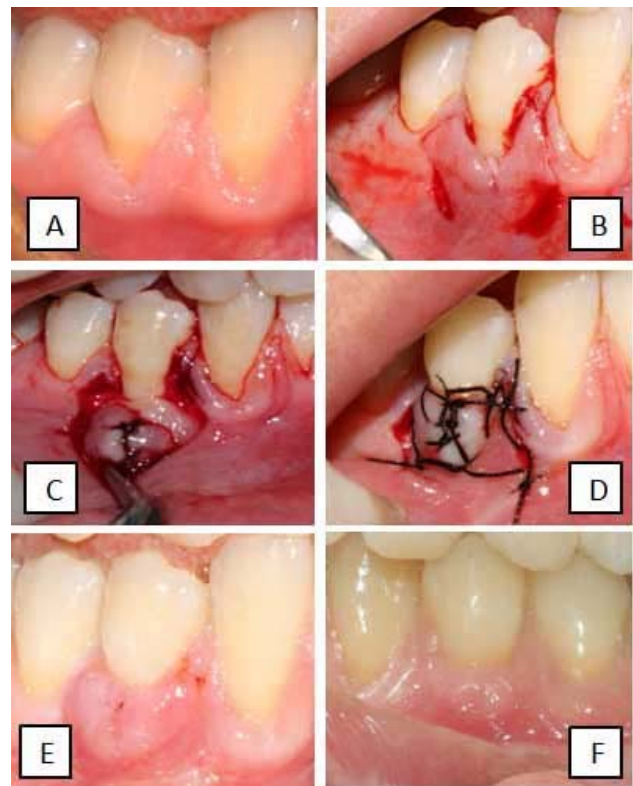


Figure 1. Treatment of gingival recession with double papilla flap and PRGF (A) the base line clinical situation of the recession. (B) incisions. (C) application of PRGF. (D) suturing. (E) after 1 month. (F) after 6 month.

movements of pedicle grafts so that they could be placed in a proper tension-free position. After scaling and root planing, coagulated PGRF was placed on the root surface and then the flap was sutured coronally at the CEJ level without any tension on PRGF. The pedicle grafts were sutured on the root surface at the midline using 5-0 silk sutures. Sling and interrupted sutures were used to stabilize the pedicle grafts. The surgical site was covered with periodontal pack and oral and written instructions were provided for the patients. Ibuprofen analgesics were administered to control the possible pain and chlorhexidine mouthwash was used to keep the surgical site clean.

The sutures were removed 10 to 14 days after surgery. The patients were followed weekly during the first month, and then monthly thereafter until the end of the study. Follow-up sessions included removal of supragingival plaque and reinstruction in oral hygiene. All the parameters were measured after 1, 3 and 6 months.

Statistical Analysis of Data

A statistical software program was used for the sta-

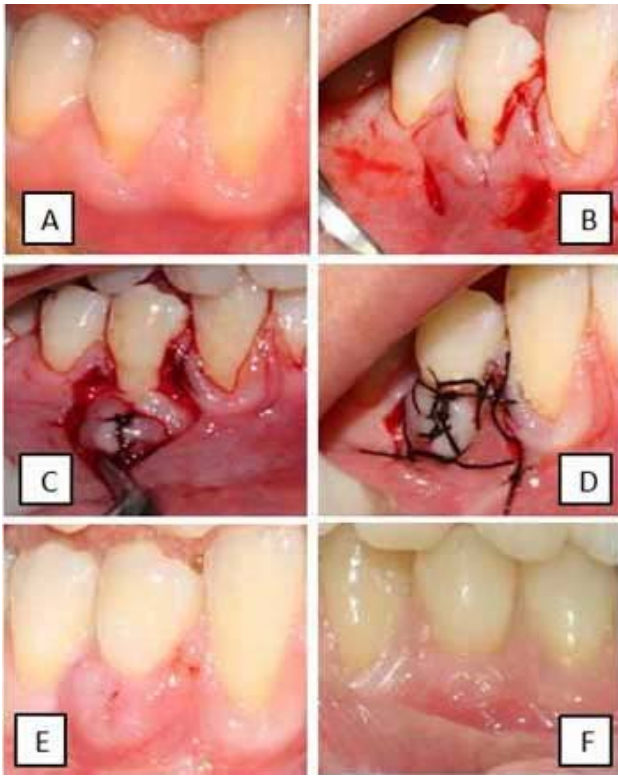


Figure 2. Treatment of gingival recession with double papilla flap and PRGF (A) the base line clinical situation of the recession. (B) incisions. (C, D) suturing. (E) after 1 month. (F) after 6 months.

tistical analysis. Data were reported as means and standard deviations (SD)

Paired t-test was used to analyze the effect of treatment modalities (between groups) as well as effect of time (baseline versus 1, 3 and 6 months) within and between the groups. Significance was set at 95% probability level ($P<0.05$).

Results

Demographic data for the test and control groups are presented in Table 1.

Baseline and 1-, 3-, and 6-month data for the test and control groups are presented in Table 2.

Healing was uneventful in all the patients (in the test and control groups), with no significant differ-

Table 1. The demographic data of the subjects

	Test	Control
Male	7	6
Female	8	9
Age	38±9	35±11
Miller's Class I	9	11
Miller's Class II	6	4
Maxillae	9	9
Mandible	6	6
Incisor	2	1
Canine	4	6
Premolar	9	8

ences in clinical parameters of CPD, CAL, WRD, KGW and HRD at baseline.

At 1, 3 and 6 months both treatment modalities resulted in significant changes in CAL, RD, RW and KG compared to baseline ($P<0.05$).

No significant differences were observed between 1- and 3-month, 1- and 6-month and 3- and 6-month intervals in CPD, CAL, RD, RW and KGW.

Statistically significant differences were observed between the test and control groups in CAL, RD, RW and KGW in favor of the PRGF group ($P<0.05$).

Discussion

Previous studies on the double papilla technique have shown variable results, and sometimes poor, in relation to covering root surfaces.²⁰

Various researches have used CTG to overcome the main disadvantage of the double papilla technique, the dehiscence of the suturing at mesial and distal papilla sites in the middle, and have reported good results.²¹⁻²³

However, use of CTG requires graft harvest from the palate, which will lead to more patient discomfort. The present study was an attempt to find an alternative for CTG with the use of PRGF^{24,25} and the results showed better outcomes compared to the double papilla technique alone.

In the present study, recession depth as a primary outcome revealed significantly more reduction in the test group (DPF+PRGF) than that in the control group (DPF).

Before surgery RD was almost equal in both groups. At baseline mean RD in the PRGF group was 1.2 (±1.13), with 1.1(±1.2) after 1 month, 1 (±0.4) after 3 months and 0.9 (±0.4) after 6 months. In the other group (without PRGF), mean RD was 1.5 (±1.4) at baseline, with 1.3 (±0.9) after 1 month, 1.1 (±0.5) after 3 months and 1.1 (±0.4) after 6 months.

Reduction of RD in the study of Harris²² with the use of DPF+CTG was better than our study results, in which the baseline range of RD was 2–7, with 0–1.5 after surgery.

PRGF yielded better results in other types of pedicle grafts, too. In a study by Faramarzi et al,¹ better results were achieved during root coverage with CAF+PRGF compared to CAF alone; PRGF enhanced the outcomes of CAF in their study.

Recession width (RW), too, decreased more in the DPG+PRGF group (4 mm), compared to 3 mm in the DPF group, indicating a significant difference between the two groups; PRGF group exhibited better results. The results in the test group in the present

Table 2. Baseline and 1-, 3-, and 6-month data for the test and control groups

Variable	Interval	Mean \pm SD	
		With PRGF	Without PRGF
PD	Before surgery	1.2 (\pm 1.13)	1.5 (\pm 1.4)
	1 month after surgery	1.1 (\pm 1.2)	1.3 (\pm 0.9)
	3 months after surgery	1 (\pm 0.4)	1.1 (\pm 0.5)
	6 months after surgery	0.9 (\pm 0.4)	1.1 (\pm 0.4)
RD	Before surgery	5.9 (\pm 0.8)	6 (\pm 1.2)
	1 month after surgery	1.8 (\pm 1)	2.7 (\pm 0.9)
	3 months after surgery	1.8 (\pm 1)	2.9 (\pm 1.1)
	6 months after surgery	1.8 (\pm 1)	3 (\pm 1.3)
RW	Before surgery	4.8 (\pm 0.6)	4.6 (\pm 0.6)
	1 month after surgery	1 (\pm 1.2)	1.6 (\pm 1)
	3 months after surgery	0.8 (\pm 0.7)	1.7 (\pm 1.2)
	6 months after surgery	1 (\pm 0.8)	1.9 (\pm 1.2)
AL	Before surgery	4.9 (\pm 0.6)	4.8 (\pm 0.7)
	1 month after surgery	1 (\pm 1.2)	2.2 (\pm 1)
	3 months after surgery	1.2 (\pm 1)	2 (\pm 1)
	6 months after surgery	1.3 (\pm 1.2)	2.1 (\pm 1)
KGW	Before surgery	2 (\pm 1.4)	2.2 (\pm 1.2)
	1 month after surgery	5.8 (\pm 1.7)	5.2 (\pm 1.4)
	3 months after surgery	5.7 (\pm 1.6)	5 (\pm 1.3)
	6 months after surgery	5.8 (\pm 1.6)	5 (\pm 1.3)
MGJ	Before surgery	7.8 (\pm 1.6)	7.3 (\pm 1.4)
	1 month after surgery	7.9 (\pm 1.5)	7.1 (\pm 1.3)
	3 months after surgery	7.7 (\pm 1.5)	7.4 (\pm 2)
	6 months after surgery	7.8 (\pm 1.6)	7.6 (\pm 1.8)
Root Coverage	1 month after surgery	79.1 (\pm 16)	64.4 (\pm 19)
	3 months after surgery	83.3 (\pm 20)	62.2 (\pm 17)
	6 months after surgery	79.1 (\pm 17)	57.7 (\pm 18)

study are not similar to Harris's²² study on DPG+CTG, in which baseline RW was 2–9 and at the end it was 0–3 and RW reduction was significant.

However, in a study by Huihuang²⁶ the baseline RW in the CAF group was 3.2 ± 0.7 , with 3.6 ± 0.4 in the CAF+PRGF group and 0.3 ± 0.8 at the end in the CAF and 0.6 ± 1.1 in the CAF+PRGF group, with no significant differences between the groups, in contrast with the results the present study. The differences between the two studies might be attributed to different flap types used in the present study.

Clinical probing depth (CPP) did not change in any of the groups in this study, with no significant differences between the groups, consistent with other studies, indicating that different methods do not affect CPP, with CPP being stable in different treatment methods.²⁴

In this study, CAL in the DPF group was 2.6 mm, which increased 3.6 mm in the DPF+PRGF, with significant differences between the groups. These results are similar to those reported by Harris²³ (DPF+CTG), in which a significant increase was

achieved in CAL, consistent with the results in the PRGF group in the present study.²³

In a study by Huang et al,²⁶ CAL improvement after 24 months in the CAF group was 3 ± 1.4 mm, with 2.5 ± 3.4 mm in the CAF \pm PRGF. Both groups exhibited significant differences compared to baseline but there were no significant differences between the groups. These results are in contrast to our study results, which might be attributed to the flap type (double pedicle), used in the present study because it has better blood supply.

The most important finding of this study was a significant increase in keratinized gingiva in both the test and control groups. Double papilla unlike other methods (CAF ,...) does not change the location of mucogingival junction and increases keratinized gingiva with lateral movement of the mesial and distal pedicles, considered as the most important advantage of double papilla flap.

In this study KGW increased 5.1 mm in the DPF+PRGF group and 3.8 mm in the DPF group. Harris²² in a study on CTG+DPF showed a significant increase in KGW from 0–7 mm at baseline to

2–10 mm, consistent with the results of the present study.

However, Faramarzi et al¹ did not report a significant increase in KG in either CAF or CAF+PRGF after 3 months, which might be attributed to the flap type they used.

In the present study, the difference between the baseline and 6-month interval was significant and this outcome was stable over time.

Mean RC in the study of Harris²² on DPF+CTG and again in another study by Harris²³ on comparison of three methods for root coverage (DPF+CTG) was better than the test group in the present study (DPF+PRGF).

Disadvantages

- 1) It is not possible to use double pedicle technique in multiple recessions.
- 2) It is not possible to use double pedicle technique if interdental papilla is narrow.

Conclusion

Although PRGF had significantly good effects when it was used with double papilla flap, CTG had more favorable effects than PRGF, indicating that it cannot be used instead of CTG. This study had a limited number of cases. It is advisable to carry out further studies with more cases.

References

1. Faramarzi M. Comparative evaluation of the clinical effects of coronal flaps with and without plasma rich in growth factors in the treatment of Miller’s Cl I and II gingival recessions. A Dissertation for a Specialty Degree in Periodontics 2006:37-42.
2. Sangnes G. Traumatization of teeth and gingiva related to habitual tooth cleaning procedures. *J Clini Periodontol* 1974;3:94-103. doi: 10.1111/j.1600-051x.1976.tb01855.x
3. Loe H, Anerud A. The natural history of periodontal disease in man: prevalence, severity, extent of gingival recession. *J Periodontol* 1992;63:489-95. doi: 10.1902/jop.1992.63.6.489
4. Albandar JM, Kingman A. Gingival recession, gingival bleeding, and dental calculus in adults 30 years of age and older in the United States. *J Periodontol* 1999;70:30-43. doi: 10.1902/jop.1999.70.1.30
5. Thomson WM, Hashim R, Pack AR. The prevalence and intraoral distribution of periodontal attachment loss in a birth cohort of 26-year-olds. *J Periodontol* 2000;71:1840-5. doi: 10.1902/jop.2000.71.12.1840
6. Wennstrom JL, Piniprato GP. Mucogingival therapy. In: Lindhe J, Karring T, Larr NP. *Clinical Periodontology and Implant Dentistry*, 4th. Munksgaard: Copenhagen; 2003. p. 550-96.
7. Borghetti A, Gardella JP. Thick gingival recession: a clinical evaluation. *In J Perio Res Dent* 1990;10:216-29.
8. Group J. Modified technique for the Sliding flap operation. *J*

9. Harris RJ. A comparative study of root coverage obtained with guided tissue regeneration utilizing a bioabsorbable membrane versus the connective tissue with partial thickness double pedicle graft. *J Periodontol* 1997;68:779-90. doi: 10.1902/jop.1997.68.8.779
10. Jepsen K, Heint B, Halben J. Treatment of gingival recession with titanium reinforced barrier membranes versus connective tissue grafts. *J Periodontol* 1998;69:383-91. doi: 10.1902/jop.1998.69.3.383
11. Piniprato GP, Ghauser C, Magnani C, Cortellini P. Resorbable membranes in the treatment of human buccal recession. *Int J Perio Res Dent* 1995;15:258-67.
12. Group J. Modified technique for the sliding flap operation. *J Periodontol* 1996;37:491-5.
13. Wennstrom JL. Mucogingival Therapy. *Ann Periodontol* 1996;1:671-701. doi: 10.1902/annals.1996.1.1.671
14. Borghetti A, Gardella JP. Thick gingival autograft for the coverage of gingival recession: a clinical evaluation. *J Perio Res Dent* 1990;10:216-29.
15. Harris RJ. Human histologic evaluation of root coverage obtained with a connective tissue with partial thickness double pedicle graft. A case report. *J Periodontol* 1999;70:813-21. doi: 10.1902/jop.1999.70.7.813
16. Cohen DW, Ross SE. The double papilla positioned flap in periodontal therapy. *J Periodontol* 1968;39:65.
17. Harris RJ. The connective tissue with partial thickness double pedicle graft: The results of 100 consecutively-treated defects. *J Periodontol* 1994;65:448-61. doi: 10.1902/jop.1994.65.5.448
18. Anitua E. Plasma rich in growth factors. A therapeutic revolution. *Ideas Y Trabajos Odontostomatologicos* 2001;2:90-7.
19. Anitua E. Plasma rich in growth factors: preliminary results of use in the preparation of future sites for implants. *Int J Oral Maxillofac Implants* 1999;14:529-35.
20. Neeta J. Double papilla repositioned flap for the treatment of isolated recession—a case report. *Singapore Dental Journal* 2013;34:25-7. doi: 10.1016/j.sdj.2013.11.005
21. Borghetti A, Louise F. Controlled clinical evaluation of the subpedicle connective tissue graft for the coverage of gingival recession. *J Periodontol* 1994;65:1107-12.
22. Harris RJ. The connective tissue with partial thickness double pedicle graft: the results of 100 consecutively-treated defects. *J Periodontol* 1994;65:448-61. doi: 10.1902/jop.1994.65.5.448
23. Harris RJ, Miller LH, Harris CR, Miller RJ. A comparison of three techniques to obtain root coverage on mandibular incisors. *J Periodontol* 2005;76:1758-67. doi: 10.1902/jop.2005.76.10.1758
24. Mohan Kumar P, Ravindra Reddy N, Sunil Kumar N, Chakrapani S. Double papilla flap technique for dual purpose. *Journal of Orofacial Sciences* 2012;4:75-8. doi: 10.4103/0975-8844.99888
25. Shah M, Gujjari SK, Gaekwad S, Dalal S. Double papilla flap with platelet rich fibrin in isolated gingival recession—a case report. *Journal of Contemporary Dental Sciences* 2012;2: 36-40.
26. Lien Huihuang, Rodrigo NEIVA. The effect of platelet rich plasma on the coronally advanced flap root coverage procedure: a pilot human Trial. *J Periodontol* 2005;76:1768-77. doi: 10.1902/jop.2005.76.10.1768