



Mucocele of the Sphenoid, Ethmoid and Frontal Sinuses Presenting with Proptosis, Visual Impairment and Diplopia

Pratiksha Yadav^{1*}

¹Department of Radio-diagnosis, Dr. D.Y. Patil Medical College, Hospital and Research Centre, Pimpri, Pune, Maharashtra, India.

Author's contribution

Author PY analyzed the case and searched literature, wrote the article and statistical analysis.

Case Study

Received 26th November 2013
Accepted 9th January 2014
Published 5th February 2014

ABSTRACT

Mucocele of the paranasal sinus is accumulation of the mucoid secretion within the sinus caused by obstruction of the sinus ostium. We report a case of paranasal sinus mucocele presented with proptosis in right eye, diplopia, visual impairment and headache. Magnetic resonance imaging(MRI) revealed a polyp in right anterior ethmoid sinus and nasal cavity resulted in mucocele of the sphenoid, ethmoid and right frontal sinuses.

Keywords: Mucocele; sphenoid sinus; para nasal sinus; proptosis.

1. INTRODUCTION

Mucocele is a benign condition, however it has tendency to expand and erodes the bony wall and may extend into the adjacent orbit or into the anterior cranial fossa. It is occasionally presents with proptosis, diplopia and visual impairment. It is rarely presents with cerebral abscess or meningitis. It is more common in frontal sinuses, less common in ethmoid sinuses and rare in sphenoid sinus, which constitutes less than 2% of all paranasal sinuses mucocele [1]. Early diagnosis and management of mucocele is important to prevent

*Corresponding author: Email: Yadavpratiksha@hotmail.com;

morbidity and potential mortality. MRI has important role to evaluate the intraorbital and intracranial extent.

2. CASE REPORT

A 24-year old female presented with a history of visual impairment since 15 days, proptosis in right eye, diplopia and headache since 4 months. CT scan of the paranasal sinuses was done which revealed cyst like expansile lesion involving sphenoid, bilateral ethmoid and right frontal sinuses Fig. 1. There was a polyp in the right anterior ethmoid sinus and nasal cavity, which was obstructing the sinus ostium. There was bony expansion of the involved sinuses. Erosion of the medial wall of both the orbits was seen. There was 5.5mm forward proptosis seen in the right eye. Marked deviated nasal septum was seen towards left side.

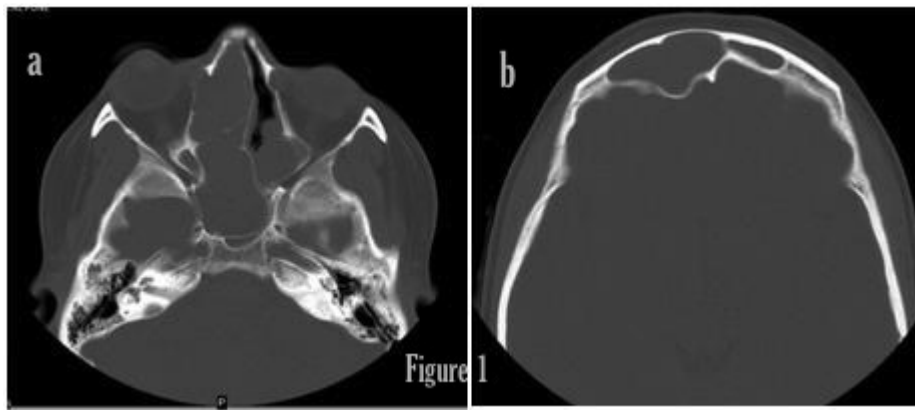


Fig. 1. (a) and (b) Axial Noncontrast CT Image in bone window shows expansion of sphenoid, ethmoid and right frontal sinus. Intraorbital extension and intracranial extension seen

MRI was advised for further evaluation and it revealed expansile homogenous lesion of the sphenoid, bilateral posterior ethmoid and right frontal sinuses, which are hypo to isointense on T1WI, hyperintense on T2WI. There was a polypoid mass in the right anterior ethmoid sinus and nasal cavity, which was obstructing the sinus ostium Figs. 2 a and b. Mucocele was seen in the sphenoid sinus Fig. 2 c. Mucocele of the left ethmoid sinus was encroaching into the posteromedial aspect of left orbit Fig. 2 f and causing proptosis. It was adjacent to left optic nerve with mild effacement of the left optic nerve Fig. 2 e which may be the cause for the diplopia. Right Frontal mucocele was encroaching the anterior aspect of the right frontal lobe Fig. 2 d. Post contrast MRI revealed peripheral enhancement of the mucosa of the paranasal sinuses suggestive of sinusitis. Mild post contrast enhancement of polyp was seen after gadolinium injection Fig. 3. There was mild mucosal thickening of the bilateral maxillary mucosa. Patient was operated for removal of the polyp and drainage of the mucocele. Post operative antibiotics were also given. Patient's diplopia and visual impairment was improved after the surgery.

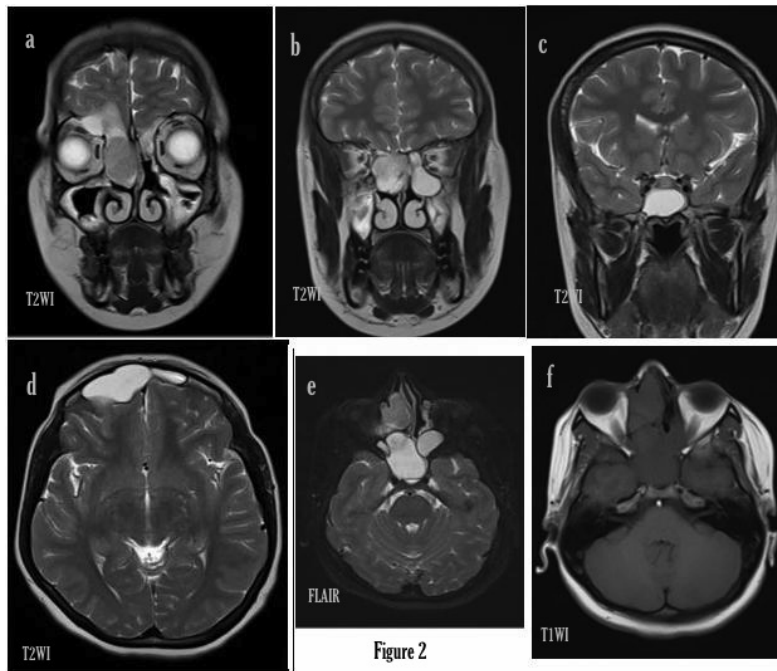


Fig. 2. (a) Magnetic resonance imaging shows a polyp in right anterior ethmoid sinus and nasal cavity (b) Homogenous hyperintense lesion seen in bilateral ethmoid sinuses (c) Sphenoid sinus (d) Right frontal sinuses with intracranial extension (e) intraorbital extension (f) T1WI MRI images show hypointense lesion in sphenoid and ethmoid sinuses.

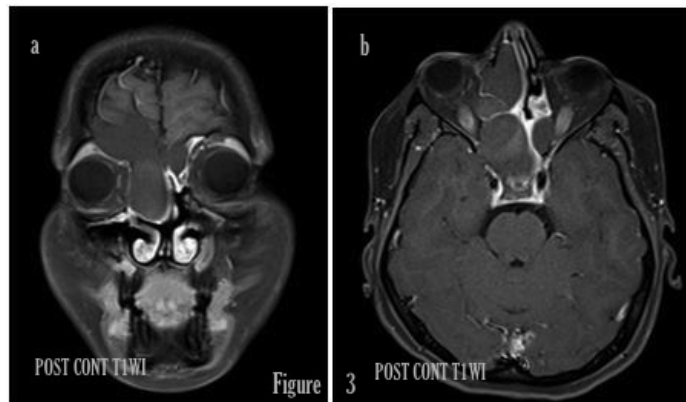


Fig. 3. (a) and (b) Post contrast MRI shows minimal enhancement in the polyp.

3. DISCUSSION

Langenbeck first described mucocele of the paranasal sinuses in 1820 under the name of hydatides. Rollet suggested the name mucocele [2]. Fronto-ethmoidal mucoceles may present headache, proptosis(83%) and diplopia(45%) [3]. Clinical features of mucocele

depends upon its anatomical site, it may be asymptomatic or can give visual impairment [3]. Mucocele is chronic, epithelial lined mucosal retention lesion due to obstruction of the sinus ostium. The obstruction may be due to congenital anomalies, trauma, neoplasm, infection, allergy or surgical procedure [4]. Continued secretion and accumulation of mucus causes increasing pressure, expansion and bony erosion of the sinus allow to expand into the orbit, intracranial, adjacent sinuses and nasal cavity [5,6]. Approximately 60–89% occurs in the frontal sinus, followed by 8–30% in the ethmoid sinuses, and less than 5% in the maxillary sinus. Sphenoid sinus mucoceles are rare (less than 2 %) [1]. Males and females are equally affected. Diagnosis of the mucocele is based on history, examination and radiological findings. CT findings of mucocele are homogenous non-enhancing expansile lesion in sinus with bone erosion and displacement of the adjacent structure. Magnetic resonance imaging findings are variable which depends upon the amount of fluid content, proteinaceous component or hemorrhage [7]. They are usually hypo or isointense on T1WI and hyperintense on T2WI. Differential diagnosis of mucocele is paranasal sinus carcinoma, Aspergillus infection or chronic infection [5]. Complications of mucocele are epidural abscess, meningitis, subdural empyema, brain abscess and visual loss [5]. When it is secondarily infected, it is called as pyocele. The treatment of mucoceles is surgical. In our case a large polyp in the right anterior ethmoid sinus and nasal cavity was obstructing the sinus ostium and was resulted in the mucocele of the right fronto-ethmoidal and sphenoid sinuses. There was frontal mucocele which was causing pressure on the anterior aspect of right frontal lobe. In our case there was mucocele in right frontal, ethmoid and sphenoid sinuses simultaneously. Surgical goal is to drain the mucocele and ventilate the sinus involved along with eradication of the mucocele with minimal morbidity and prevention of recurrences [8,9].

4. CONCLUSION

Mucocele of the paranasal sinus is an important cause for proptosis, diplopia and visual impairment. Early diagnosis and timely management is of paramount importance to prevent the intracranial and intraorbital extension and its complications. MRI is the best modality to evaluate the extent of the mucocele. Contrast enhanced MRI is useful in differentiating mucocele from Sino nasal tumours.

CONSENT

Author declares that 'written informed consent was obtained from the patient for publication of this case report and accompanying images.

ETHICAL APPROVAL

Approval from the ethical committee of the hospital was obtained.

COMPETING INTERESTS

Author has declared that no competing interests exist.

REFERENCES

1. Arrue P, et al. Mucoceles of the paranasal sinuses: Uncommon location. *J Laryngol Otol.* 1998;112:840–4.

2. Alberti PW, Marshall HF, Munro Black JI. Fronto-ethmoidal Mucocele as a cause of Unilateral Proptosis. *Br J Ophthalmol.* 1968;52:833.
3. Sushil Kumar Aggarwal, Kranti Bhavana, Amit Keshri, Raj Kumar, Arun Srivastava. Frontal sinus mucocele with orbital complications: Management by varied surgical approaches. *Asian J Neurosurg.* 2012;7(3):135–140
4. Yap SK, Aung T, Yap EY. Frontal Sinus Mucoceles Causing Proptosis—Two Case Reports. *Ann Acad Med Singapore.* 1998;27:744-7
5. Beatriz PeralCagigal, et al. Frontal sinus mucocele with intracranial and intraorbital extension. *Med Oral Patol Oral Cir Bucal.* 2006;11:527-30.
6. Suri A, Mahapatra AK, Gaikwad S, Sarkar C. Giant mucoceles of the frontal sinus: a series and review. *J Clin Neurosci.* 2004;11:214-8.
7. BK Sinha, Adhikari P. Sphenoid sinus mucocele with blindness. *Nepal Med Coll J.* 2008;10(3):204-206
8. Rubin JS, Lund VJ, Salmon B. Frontoethmoidectomy in the treatment of mucoceles: A neglected operation. *Arch Otolaryngol Head Neck Surg.* 1986;112:434–6.
9. Olivier Malard, et al. Spontaneous Sphenoid Sinus Mucocele Revealed by Meningitis and Brain Abscess in a 12-Year-Old Child *AJNR.* 2004;25:873-875.

© 2014 Yadav; This is an Open Access article distributed under the terms of the Creative Commons Attribution License (<http://creativecommons.org/licenses/by/3.0>), which permits unrestricted use, distribution and reproduction in any medium, provided the original work is properly cited.

Peer-review history:
The peer review history for this paper can be accessed here:
<http://www.sciencedomain.org/review-history.php?iid=422&id=12&aid=3543>