



Fatal Outcome in a Patient with Acute Dilatation of Stomach without Perforation – A Case Report

Subhrajit Deb^{1*}, Rupesh Pakrasi¹, Darshna Dutta² and Achyut Kanungo²

¹Department of General Surgery, Calcutta National Medical College and Hospital, Kolkata-700014, India.

²Institute of Postgraduate Medical Education and Research, Kolkata-700020, India.

Authors' contributions

This work was carried out in collaboration among all authors. Authors SD and AK designed and produced majority of the manuscript. Author SD was the supervising surgeon for this patient and was involved in critically revising the manuscript. Author RP was directly involved in managing this patient and critically revising the manuscript. Authors DD and AK obtained all clinical images for and involved in the drafting of, the manuscript. All authors read and approved the final manuscript.

Article Information

Editor(s):

(1) Dr. Ashish Anand, GV Montgomery Veteran Affairs Medical Center, USA.

Reviewers:

(1) Nuray Colapkulu-Akgul, Turkey.

(2) Ramesh Kumar Aggarwal, NDMC Medical College and Hindu Rao Hospital, India.

Complete Peer review History: <https://www.sdiarticle4.com/review-history/74906>

Case Study

Received 09 August 2021

Accepted 18 October 2021

Published 25 October 2021

ABSTRACT

Aims: Acute gastric dilatation (AGD) is the radiological finding of a massively enlarged stomach as seen on a plain film x-ray or CT scan of the abdomen. Due to a lack of physician awareness, it may go undiagnosed and has a high mortality if not treated promptly. Multiple aetiologies exist in this condition which can lead to ischemic necrosis and perforation of the stomach. We report its presentation in a patient of schizophrenia on anti-psychotic and anti-muscarinic agents, to share our challenges in diagnosing and treating this condition.

Presentation of Case: A 41-year-old patient presented with acute pain abdomen and distension. The patient was hemodynamically unstable. Blood analysis showed leucocytosis and raised CRP whereas serum amylase was normal. Straight X-ray abdomen showed gaseous dilatation of stomach. Patient did not improve on conservative management. Exploratory laparotomy revealed a hugely dilated stomach. Gastric decompression with anterior gastrostomy with gastropexy was performed. Patient was kept in intubated state in the post operative period in ICU and was maintained on antibiotics and inotropes. Although recovering initially, he succumbed on post operative day 3, due to multi organ dysfunction syndrome.

Discussion: AGD is an emergency requiring immediate intervention. Early detection by clinical examination and imaging followed by surgical intervention is the key for managing AGD.

Conclusion: Our case report demonstrates the importance of clinical identification of AGD and subsequent diagnosis and management. A patient with acute onset abdominal distention should be urgently investigated by proper imaging modalities. Recognition and diagnosis of this condition is required for appropriate patient management. In addition, our case report adds to the complication of antipsychotic and antimuscarinic agents resulting in this condition.

Keywords: *Abdominal distention; acute gastric dilatation (AGD); anti-muscarinic agents; trihexyphenidyl.*

1. INTRODUCTION

Acute gastric dilatation (AGD) was first reported by S.E. Duplay in 1833, yet no precise definition of this condition is available in scientific literature, due to a scarcity of cases reported since. It is generally described as the radiological finding of a massively enlarged stomach, with gas or fluid, as seen on plain film abdominal X-ray (AXR) or computerized tomography (CT) scan of the abdomen [1].

The aetiologies of AGD can be either mechanical obstruction or non-mechanical distension of the stomach. Various conditions resulting in mechanical obstruction include pyloric stenosis, gastric volvulus, intra-abdominal adhesions/strictures and superior mesenteric artery (SMA) syndrome. Non-mechanical aetiologies include eating disorders, medication, electrolyte abnormalities, Prader-Willi syndrome and gastroparesis [2]. Predisposing factors include lifestyle habits, underlying morbidities, acute necrotizing inflammation, vascular insufficiency and post-operative complications. Some studies do report use of antipsychotics and anti-cholinergic drugs may result to gastroparesis and ileus [3].

AGD involves compromise of the otherwise rich gastric vascular supply due to the maximal dilatation of the stomach, resulting in venous compression, followed by arterial ischemia, which can prove fatal if sequelae like gastric emphysema or perforation occur [4].

Thus, the principle of treatment involves decompression of the stomach. In most cases of AGD, surgery was necessary to prevent or treat the complications [2,4-8]. But early diagnosis of the condition with prompt gastric decompression avoids unnecessary operative intervention.

Here we present a case of a patient with known psychiatric illness, under treatment with anti-

psychotics and anti-cholinergic drugs, presenting with massive AGD and ischaemic changes.

2. CASE REPORT

A 41-year-old gentleman, referred from a peripheral hospital presented to our emergency department (ER) with acute pain abdomen and distension. The distension had started two days back and patient was unable to take any oral feed, for which he was admitted. Since the onset of symptoms, he had multiple episodes of vomiting and was treated with intravenous fluids. Before presenting to our ER, he developed acute pain abdomen with rapidly progressive abdominal distension over approximately eight hours. Upon enquiry, it was reported that the patient was being treated for schizophrenia with risperidone and trihexyphenidyl for last one year.

On examination, the patient was hemodynamically unstable with severe dehydration, hypotension and tachycardia. He had massive abdominal distension with tympanic note all over the abdomen. Emergency laboratory investigations revealed total leucocyte count of 32000/mm³, haemoglobin 5.5 g/dL and raised CRP levels. Neutrophil count was 85% but serum amylase levels were within normal limits. Erect X-Ray abdomen revealed hugely dilated stomach occupying almost half of the abdominal cavity [Fig. 1]. Plan for CT abdomen was aborted as patient was unstable.

Resuscitation started with infusion of 1 litre of crystalloids over 15 minutes followed by 1 litre in a span of 30-45 minutes. Nasogastric tube was inserted, which failed to pass beyond 40 cm from central upper incisors. On urinary catheterisation, minimal amount of dark yellow coloured urine was observed.

Initially, APACHE II score was 22, which decreased by two points after two hours of

resuscitation. With no clinical improvement in sight, decision was taken to perform emergency exploratory laparotomy.

On opening the abdomen through upper midline incision, it was found that stomach was hugely dilated [Fig. 2].

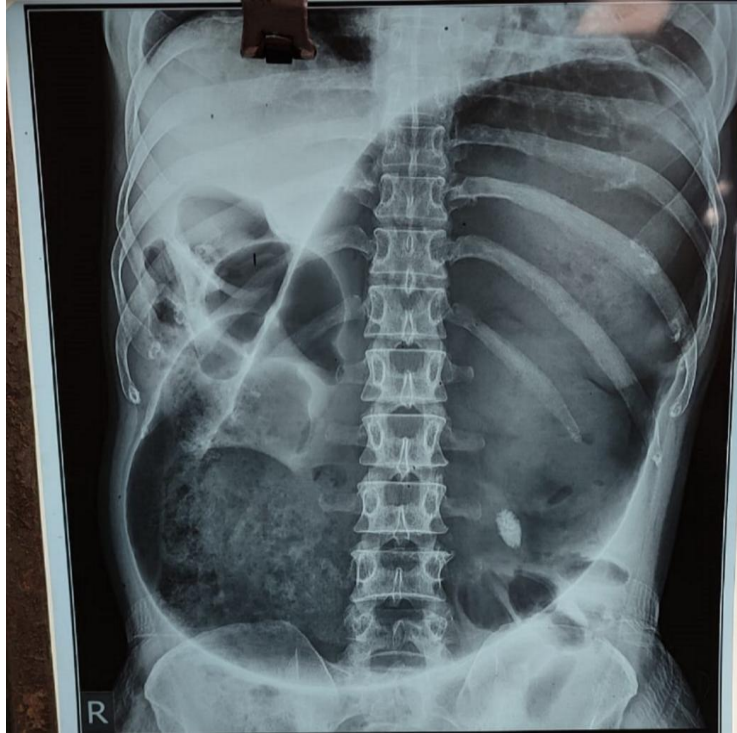


Fig. 1. X-ray chest and abdomen showing massive gastric dilation

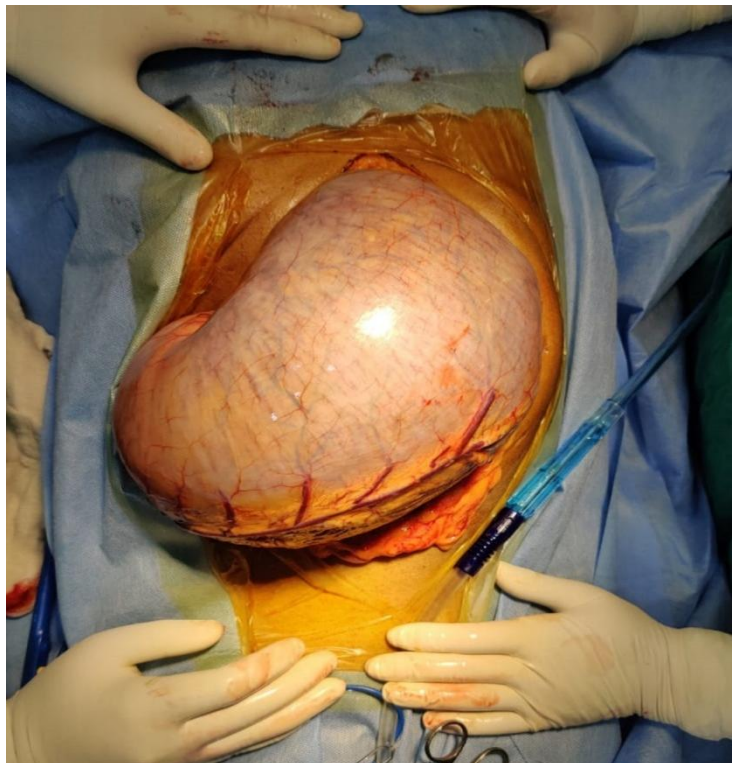


Fig. 2. Exploratory laparotomy showed stomach was hugely dilated

Stomach was decompressed by a 2 cm incision over the anterior surface of stomach and a sweet odour was noted. Two litres of thick black fluid were aspirated to examine the mucosa. Blackish discoloration and ischemic changes were seen over the mucosal surface of the greater curvature, fundus and posterior surface of stomach [Fig. 3]. The anterior surface appeared to be normal. No features of any perforation were detected.

A bail out procedure was decided intraoperatively as it was impossible to perform complete or partial gastrectomy due to haemodynamic instability of the patient. Though a relook laparotomy with gastrectomy (if required) was planned after 48 – 72 hours. Gastrostomy was created by inserting a 18F Foley's catheter through the anterior surface of stomach for continuous suction irrigation of the stomach mucosa. Gastrostomy was planned as it is procedure of choice in many cases of acute gastric dilation [9]. Gastropexy was done by fixing the borders of the stomach with adjacent structures to reduce chances of gastric volvulus. Proper peritoneal lavage was done and abdomen closed in layers after putting two 30F abdominal drains over the hepatorenal pouch and the lesser sac. A revision laparotomy was

planned within 48 hours of patient stabilization in ICU.

Post-operatively, the patient was shifted to the ICU while intubated. Three units of packed RBC and four units of FFP were transfused. He was kept on antibiotics and inotropes. The patient improved initially, but later deteriorated and succumbed on POD 3 to multi organ dysfunction syndrome. Relook laparotomy couldn't be conducted as patient already developed MODS and was haemodynamically unstable.

3. DISCUSSION

AGD may occur due to variable aetiologies, such as postoperative complication after abdominal surgery, anorexia nervosa, bulimia nervosa, psychogenic polyphagia, trauma, electrolyte disturbance or diabetes mellitus [5-8]. The pathophysiological mechanisms of AGD and its complications are not well known. Some previous studies have demonstrated that increased intra-gastric pressure due to SMA syndrome as a contributing factor of AGD [10,11]. Some have suggested that AGD may be a functional condition secondary to a regional organic disease, such as pancreatitis, gallbladder stone, peptic ulcer or appendicitis [12,13].

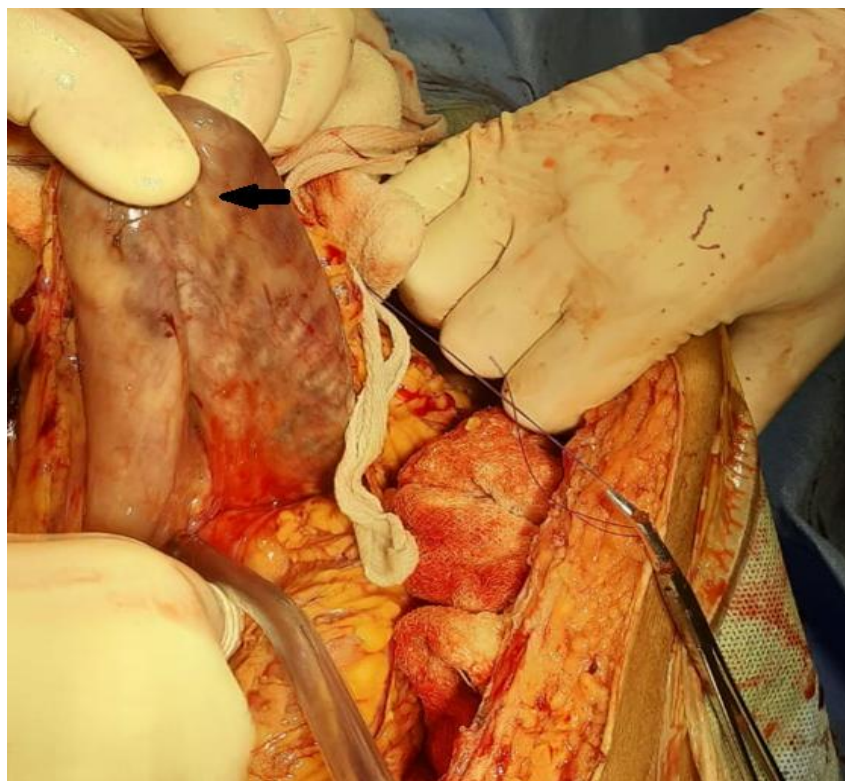


Fig. 3. Ischaemic changes over posterior surface of stomach (arrow)

In our case, the patient had history of schizophrenia and was on long term risperidone and trihexyphenidyl. Trihexyphenidyl (anti-cholinergic) has anti-muscarinic effect and prevents extrapyramidal symptoms in schizophrenic patients. Anti-muscarinic drugs are known to cause gastroparesis and may also result in ileus [3]. Study says that second generation antipsychotics may also cause gastroparesis [3]. Our patient did not have any past history of comorbidities, trauma or surgery. On thorough clinical examination, no intra-abdominal pathology such as pancreatitis, etc. was found. It appears chronic intake of anti-muscarinic drugs (trihexyphenidyl) and second generation anti-psychotics (risperidone) might be the cause of AGD in our case, as other obvious aetiologies were ruled out.

Plain abdominal x-rays may reveal an air-fluid level in a markedly distended stomach without small bowel gas shadows. The investigation of choice is an abdominal CT scan that clearly demonstrates gastric distension [11]. CT scan should be performed only after stabilisation of the patient. In case of perforation, radiological investigations demonstrate pneumoperitoneum. An upper endoscopy has value in tracing the obstructive aetiology and assessing for ischemic changes in the mucosa. It provides the benefit of suctioning trapped air. However, perforation must be excluded via appropriate imaging studies [14].

Recovery may occur with nasogastric decompression in some cases. Intra-gastric pressure can be reduced by partial decompression by nasogastric tube drainage, lowering risk of necrosis and perforation. After binge-eating, treatment with gastric decompression using a normal sized nasogastric tube is generally unsuccessful [15,16].

Hence early detection and intervention is the key for managing AGD. Proper hydration, nasogastric suctioning and supportive therapy is the first line management, failure of which mandates surgical intervention. The patient was referred after 48 hours of development of symptoms. Conservative management failed and exploratory laparotomy revealed ischaemic changes of stomach without perforation. Gastrostomy may be considered in highly morbid patients where gastrectomy isn't possible.

4. CONCLUSION

Our case report demonstrates the importance of clinical identification of AGD. A patient with acute

onset abdominal distension should be investigated urgently for appropriate management. In addition, our case report adds to the complication of antipsychotic and antimuscarinic agents resulting in this condition.

CONSENT

All authors declare that 'written informed consent was obtained from the patient's family for publication of this case report and accompanying images.

ETHICAL APPROVAL

As per international standard written ethical approval has been collected and preserved by the author(s).

COMPETING INTERESTS

Authors have declared that no competing interests exist.

REFERENCES

1. Shaikh D, Jyala A, Mehershahi S, Sinha C, Chilimuri S. Acute Gastric Dilatation: A Cause for Concern. *Case Reports in Gastroenterology*. 2021;15(1):171-177.
2. Van Eetvelde E, Verfaillie L, Van De Winkel N, Hubloue I. Acute gastric dilatation causing acute limb ischemia in an anorexia nervosa patient. *J Emerg Med*. 2014;46(5):e141-3
3. Usai-Satta P, Bellini M, Morelli O, Geri F, Lai M, Bassotti G. Gastroparesis: New insights into an old disease. *World Journal of Gastroenterology*. 2020;26(19):2333-2348.
4. Moslim MA, Mittal J, Falk GA, Ustin JS, Morris-Stiff G. Acute massive gastric dilatation causing ischaemic necrosis and perforation of the stomach. *BMJ Case Rep*. 2017;2017:bcr2016218513.
5. Cogbill TH, Bintz M, Johnson JA, Strutt PJ. Acute gastric dilatation after trauma. *J Trauma*. 1987;27(10):1113-1117.
6. Nakao A, Isozaki H, Iwagaki H, Kanagawa T, Takakura N, Tanaka N. Gastric perforation caused by a bulimic attack in an anorexia nervosa patient: Report of a case. *Surg Today*. 2000;30(5):435-437.
7. Turan M, Sen M, Canbay E, Karadayi K, Yildiz E. Gastric necrosis and perforation caused by acute gastric dilatation: Report of a case. *Surg Today*. 2003;33(4):302-304.

8. Todd SR, Marshall GT, Tyroch AH. Acute gastric dilatation revisited. *Am Surg.* 2000;66(8):709-710.
9. Noshier JL, Bodner LJ, Girgis WS, Brolin R, Siegel RL, Gribbin C. Percutaneous gastrostomy for treating dilatation of the bypassed stomach after bariatric surgery for morbid obesity. *AJR Am J Roentgenol.* 2004;183(5):1431-5.
DOI: 10.2214/ajr.183.5.1831431
PMID: 15505316.
10. Pentlow BD, Dent RG. Acute vascular compression of the duodenum in anorexia nervosa. *Br J Surg.* 1981;68(9):665-666.
11. Adson DE, Mitchell JE, Trenkner SW. The superior mesenteric artery syndrome and acute gastric dilatation in eating disorders: A report of two cases and a review of the literature. *Int J Eat Disord.* 1997;21(2):103-114.
12. Backett SA. Acute pancreatitis and gastric dilatation in a patient with anorexia nervosa. *Postgrad Med J.* 1985;61(711):39-40.
13. Gondos B. Duodenal compression defect and the superior mesenteric artery syndrome 1. *Radiology.* 1977;123(3):575-80.
DOI: 10.1148/123.3.575
PMID: 870933.
14. Maung H, Buxey K, Studd C, Ket S. Acute gastric dilatation in a bulimic patient. *Gastrointestinal Endoscopy.* 2017;85(2):455-457.
15. Lunca S, Rikkers A, Stanescu A. Acute massive gastric dilatation: Severe ischemia and gastric necrosis without perforation. *Rom J Gastroenterol.* 2005;14(3):279-283.
16. Saul SH, Dekker A, Watson CG. Acute gastric dilatation with infarction and perforation. Report of fatal outcome in patient with anorexia nervosa. *Gut.* 1981;22(11):978-983.

© 2021 Deb et al.; This is an Open Access article distributed under the terms of the Creative Commons Attribution License (<http://creativecommons.org/licenses/by/4.0>), which permits unrestricted use, distribution, and reproduction in any medium, provided the original work is properly cited.

Peer-review history:

The peer review history for this paper can be accessed here:
<https://www.sdiarticle4.com/review-history/74906>