



Single-Strip Pericardium Technique for Pulmonary Valve Reconstruction in Tetralogy of Fallot: A Case Report

Ismail Dilawar¹, William Makdinata^{1*}, Imamurahman Taslim¹
and Moira Setiawan²

¹Division of Cardiac Surgery, Department of Surgery, Faculty of Medicine, Cipto Mangunkusumo Hospital, Universitas Indonesia, Jakarta, Indonesia.

²Faculty of Medicine, Universitas Indonesia, Jakarta, Indonesia.

Authors' contributions

This work was carried out in collaboration among all authors. All authors read and approved the final manuscript.

Article Information

Editor(s):

(1) Dr. Yasushi Shibata, University of Tsukuba, Japan.

Reviewers:

(1) Faehaa Azher Al-Mashhadane, University of Mosul, Iraq.

(2) Marcel Vasconcellos, Centro Universitário Serra dos Órgãos, Brazil.

(3) Marcos Mello Moreira, Brazil.

Complete Peer review History: <https://www.sdiarticle4.com/review-history/75385>

Case Study

Received 12 August 2021

Accepted 24 October 2021

Published 28 October 2021

ABSTRACT

Right ventricular outflow tract (RVOT) dysfunction requiring pulmonary valve reconstruction following the surgical repair of Tetralogy of Fallot (ToF) is common. It remains a challenge in the pediatric population due to the small size of the pulmonary valve annulus, especially when the pulmonary valve is still growing in size. The use of monocusp valves and xenograft valved conduits tend to have long-term functional limitations arise over time, leading to early valve re-reconstruction or re-replacement. Studies reported the use of the Ozaki technique to reconstruct the pulmonary valve to overcome this problem. However, our centre did not have access to the equipments needed for the Ozaki procedure. We had an 8-year-old with ToF who was scheduled for total correction of ToF. However, after exposing the RVOT, we found that the pulmonary valves have fused and retracted bicuspid leaflets. We decided to reconstruct the pulmonary valve using a single strip of autologous pericardium. Postoperative transesophageal echocardiography showed mild pulmonary stenosis with a gradient of 33 mmHg without pulmonary regurgitation, as well as good

*Corresponding author: E-mail: william.makdinata@yahoo.co.id;

neo pulmonary leaflet motion and coaptation. The patient was discharged without any complications. With this technique, we can create three equal-sized leaflets without the need of any special equipment and still achieve physiological valve hemodynamics while being more economic, easily reproducible, and much simpler to shorten bypass time. If required, the procedure can also be done together with a trans-annular patch in the correction of ToF.

Keywords: Pulmonary valve reconstruction; single strip pericardium; tetralogy of fallot.

1. INTRODUCTION

Tetralogy of Fallot, a type of cyanotic congenital heart defect, is characterised by an overriding aorta, a ventricular septal defect, right ventricular outflow tract obstruction, and right ventricular hypertrophy. These features cause deoxygenated blood to be diverted to the systemic circulation and cause cyanosis and hypoxemia. If not corrected, it may cause poor exercise tolerance, failure to thrive, recurrent respiratory tract infections, and heart failure [1]. To date, there has yet to be a standardized method for pulmonary valve reconstruction. Popular methods include the use of xenograft valved conduits or monocusp valves. However, despite a range of options available for pulmonary valve replacement, progressive functional limitations caused by those valves lead to a further replacement in the future. The use of valved conduits lead to frequent re-operations due to the change in the diameter of the valve's annulus as the pediatric patient grows in size [2], not to mention it is expensive and subjects the patient to lifetime use of anticoagulants [3,4]. On the other hand, although monocusp valves prevent immediate pulmonary insufficiency [5], with time, monocusp valves tend to lead to right ventricular overload due the unnatural form of the single valve and its inability to withstand the backflow of blood in the main pulmonary artery [6]. Therefore, both these methods have limited competence in the long term and are also not broadly reproducible. To overcome this problem, surgeons have considered the use of autologous pericardium to reconstruct the pulmonary valve similar to a native pulmonary valve as they provide good hemodynamics and long-term durability [7].

In a study done by Ozaki, aortic valve neocuspidization using autologous pericardium was proven to be a safe, inexpensive, reproducible and effective alternative for aortic valve replacement in adults [8]. A study by Baird et al. showed acceptable early results and demonstrated aortic annular growth in the pediatric population [9]. However, a specific

sizing device is required to measure the size of the leaflets, in which our center do not have access to. Thus, we report a case where a single strip of the pericardium was used to create a three-leaflet pulmonary valve without the need to measure individual leaflets but still formed a physiological valve, a suitable and applicable technique for developing countries with limited medical facilities and equipment.

2. CLINICAL CASE

An 8-year-old boy was referred to our hospital with progressive limitation of daily activities with signs of episodic central cyanosis but no complaints of dyspnea. On physical examination, a grade 2 pansystolic murmur was heard in the apex. Clubbing fingers were also found during examination. A chest X-ray revealed a "boot-shaped" appearance, with an upturned apex and a concave pulmonary segment. An echocardiogram performed a week before the surgery showed an overriding aorta (>50%), severe infundibular pulmonary stenosis, left aortic arch, and single coronary artery, with no atrial septal defect nor any coarctation of the aorta. Cardiac catheterization prior to surgery showed the presence of the innominate vein, infundibular pulmonary stenosis, and a confluent pulmonary artery (PA). The diameters of the right pulmonary artery and the left pulmonary artery are 8.44 mm and 9.36 mm respectively, with a half size of 9.00 mm. Cardiac catheterization also showed a single, large malaligned ventricular septal defect (VSD) with an overriding aorta (50%), good left ventricular (LV) volume and a single coronary ostium, the absence of a patent ductus arteriosus (PDA), minimal collateral arteries, and a left aortic arch with the descending aorta being 8.07 mm in diameter. The McGoon ratio is 2.21, while the Nakata index is 208. The patient was planned for total correction of ToF.

3. SURGICAL TECHNIQUE

A median sternotomy was performed. A portion of the anterior pericardium was harvested

according to the necessary size. The excised pericardium is then immersed in 0.6% glutaraldehyde solution for 10 minutes. The treated pericardium is then rinsed and soaked in saline 3 times for 5 minutes. After establishing cardiopulmonary bypass and cardioplegic arrest, the right atrium is incised and left ventricular venting was performed through the patent foramen ovale (PFO). Afterwards, the pulmonary artery is incised and the RVOT is exposed to the resect the RVOT tissue to relieve the stenosis. However, we found that the pulmonary valves have fused and retracted bicuspid leaflets. Thus, we decided to reconstruct the pulmonary valve. The pulmonary leaflets were carefully cut out with scissors and a scalpel as not to damage the annulus. The annulus of the pulmonary valve was then measured with a hegar dilator according to the patient's body weight (Fig. 1). The diameter of the RVOT annulus and the height of the pulmonary commissure are measured. These measurements would be used to measure the length and width of the pericardium respectively to obtain a rectangular-shaped pericardium (Fig. 2). The two ends of the pericardium would then be joined to form a cylindrical tube, which is then adjusted to the pulmonary valve annulus. Excess pericardium was trimmed off and the upper edge of the pericardium was sewn with 5-0 polypropylene

suture to the pulmonary annulus and transannular pericardial patch, in a way that the pericardium tube leads towards the right ventricle (Fig. 3). Then, the pericardial tube was inverted upwards so that the inside of the pericardial tube is now outside (Fig. 4). The lowest point of the pericardium was sutured with 5-0 polypropylene suture to the lowest point of the commissures, in reference to the three previous commissure points, suturing upward towards the end of the commissure in which the direction of the neo-commissure sutures were perpendicular to the annulus. After that, sutures made along the commissure is fixated with a pledget, where two sides were fixated to the annulus and one was fixated to the RVOT roof made from the transannular patch (Fig. 5). A valve competency test was carried out using saline liquid with the result as shown in (Fig. 6). The time taken for cardiopulmonary bypass as well as aortic cross clamp time was 149 minutes and 56 minutes respectively. Immediate postoperative transesophageal echocardiography evaluation revealed a PFO, a left-to-right shunt, no residual VSD, mild pulmonary stenosis (gradient is 33 mmHg) without pulmonary regurgitation, as well as good neo pulmonary leaflet motion and coaptation. The patient was discharged after 8 days without any complications.

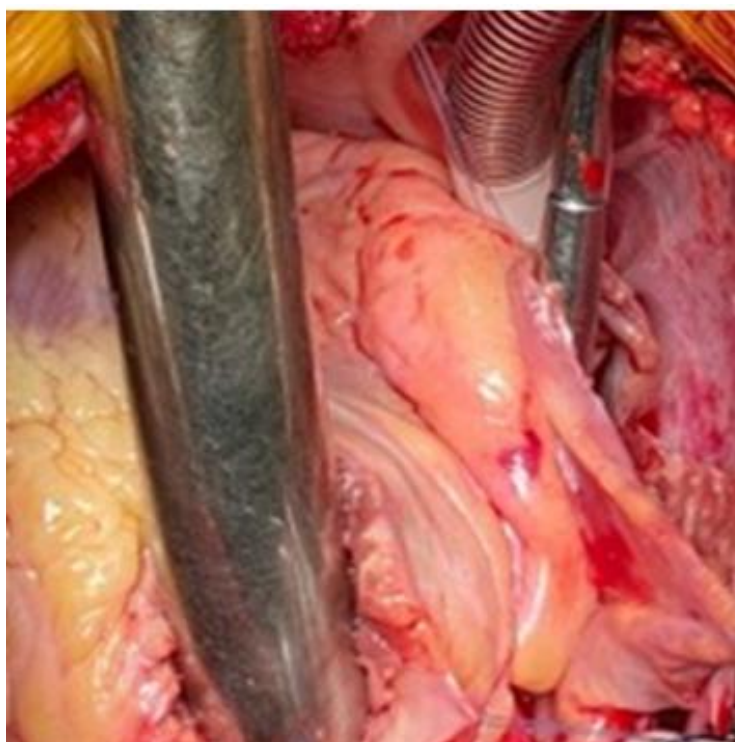


Fig. 1. Measurement of RVOT diameter using a Hegar dilator



Fig. 2. A Rectangular-shaped pericardium was obtained with the circumference of the pulmonary annulus as the length and height of the commissure as the width

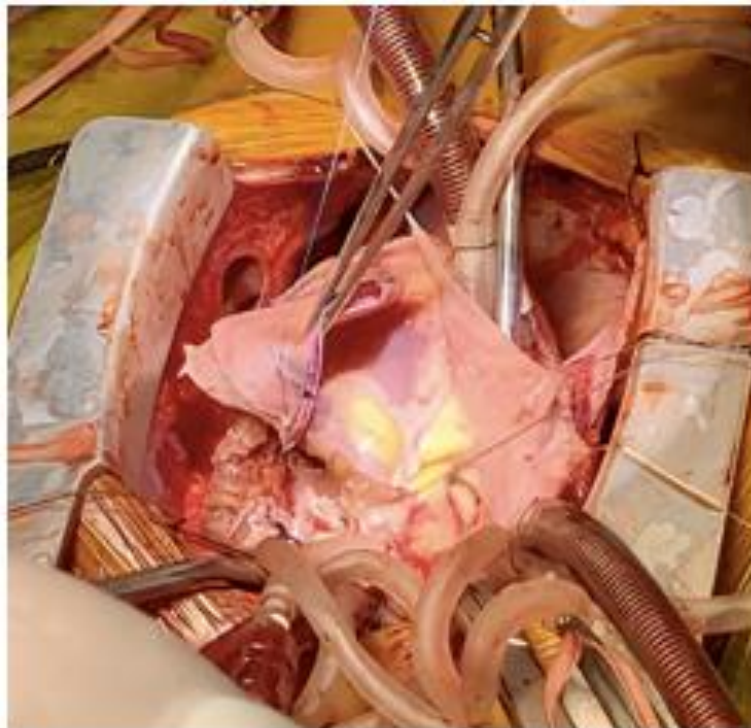


Fig. 3. The upper edge of the pericardium was sewn to the pulmonary annulus

4. DISCUSSION

RVOT dysfunction such as pulmonary regurgitation and pulmonary stenosis requiring pulmonary valve reconstruction is common and remains challenging in the pediatric population following surgical repair of ToF. Monocuspid

valves implantations carry a risk of endocarditis and the risk of pulmonary regurgitation as the pulmonary annulus continues to grow [7]. On the other hand, xenograft valved conduits are not readily available in some countries, are prone to stenosis and lacks growth potential [10]. Reconstruction of the pulmonary valve using

bovine pericardium has shown good outcomes but is more expensive, not readily available, and comes with a risk of infection [11]. Therefore, in this regard, the use of autologous pericardium is the better choice.

The aortic valve neocuspidization (AVNeo) or Ozaki procedure is technically reproducible and have acceptable results for both aortic and pulmonary valves in adult and pediatric patients [9,12]. The Ozaki procedure needs special equipments, which include the AVNeo template and sizing device. However, these equipments are not readily available in our center. A single strip of the pericardium as an alternative procedure can be done more simply as we can

create three equal-sized leaflets to optimize coaptation height and distribute tension equally throughout the valve using an old commissure point, without the need of any special equipment. Thus, the method of using a single strip of the pericardium is more favorable as the overall procedure does not require any specific devices and is much simpler, thus shortening surgical bypass time. This technique is also more economical and easily reproducible. If required, the procedure can be done together with a trans-annular patch in the correction of ToF. However, this is a relatively new technique, so further research is still needed to assess the valve's durability as well as long term outcomes.

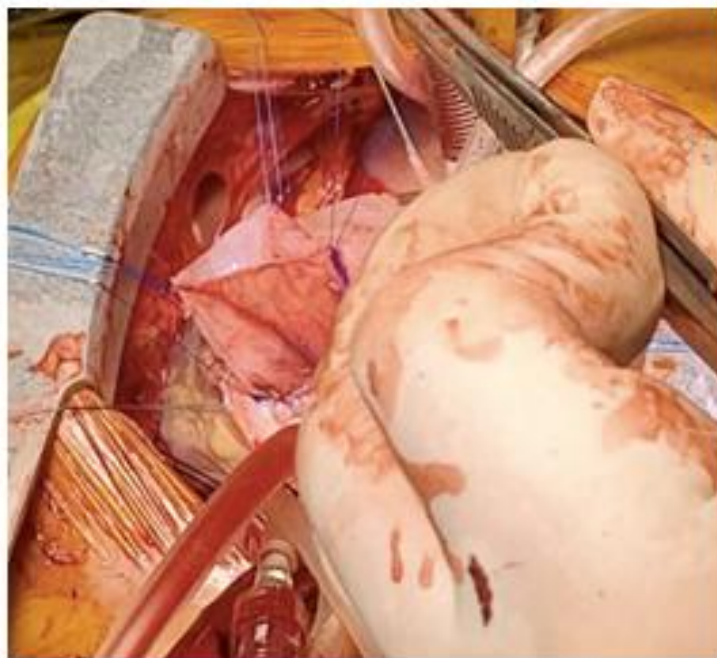


Fig. 4. The pericardial tube is inverted and sewn vertically towards the end of the commissure

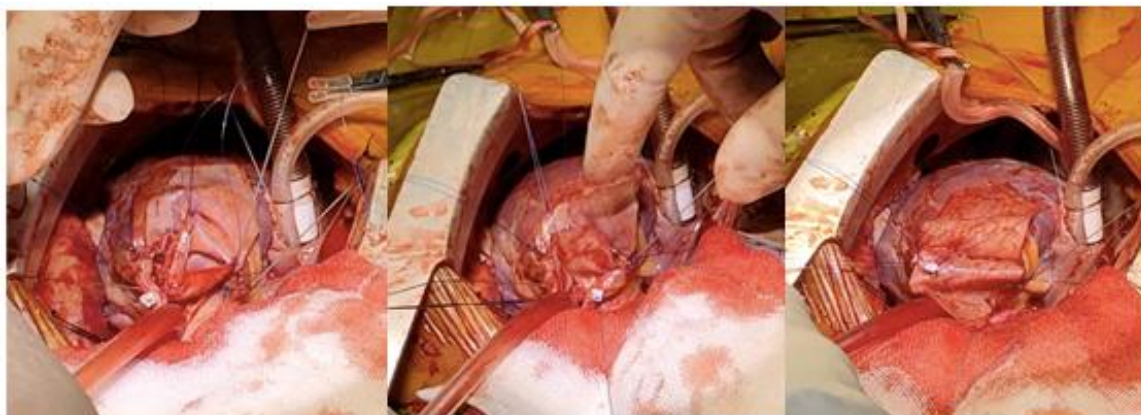

Fig. 5. Fixation of the suture along the neo-commissure with pledget

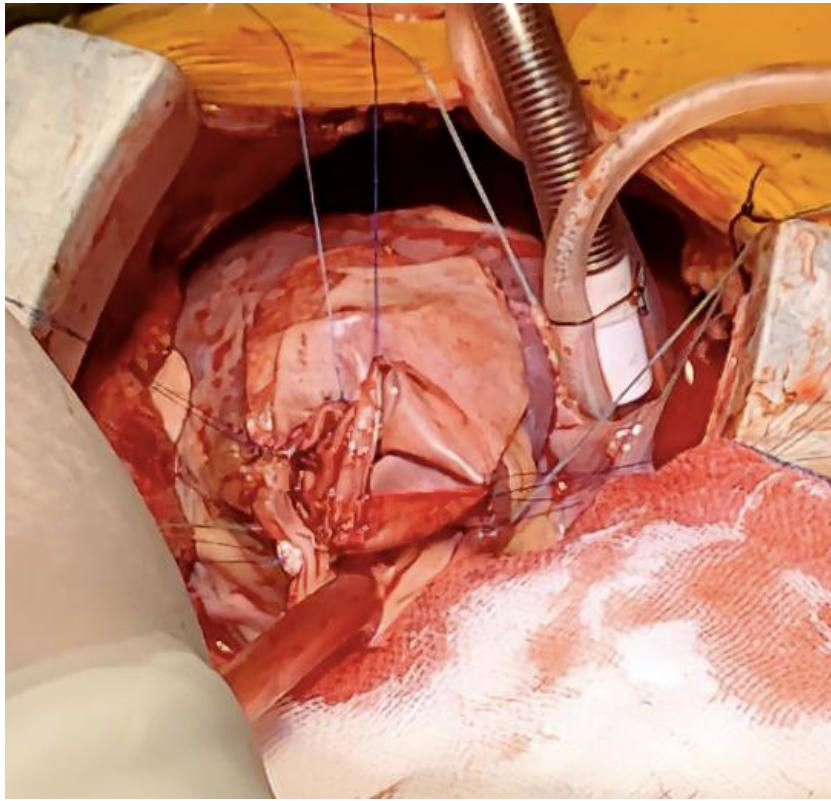


Fig. 6. Results

5. CONCLUSION

Using a single strip of pericardium for pulmonary valve reconstruction in ToF is feasible without the need for equipments such as templates and sizing devices. This is favorable especially for developing countries with limited facilities. This procedure can also be done together with a trans-annular patch to correct ToF, With this technique, we can create three equal-sized leaflets without the need of any special equipment and still achieve physiological valve hemodynamics while being more economic, easily reproducible, and much simpler to shorten bypass time.

CONSENT

As per international standard or university standard, patients' written consent has been collected and preserved by the author(s).

ETHICAL APPROVAL

As per international standard or university standard written ethical approval has been collected and preserved by the author(s).

COMPETING INTERESTS

Authors have declared that no competing interests exist.

REFERENCES

1. Wilson R, Ross O, Griksaitis M. Tetralogy of Fallot. BJA Education. 2019;19(11):362-369.
2. Yuan S, Mishaly D, Shinfeld A, Raanani E. Right ventricular outflow tract reconstruction: Valved conduit of choice and clinical outcomes. Journal of Cardiovascular Medicine. 2008;9(4):327-337.
3. Pibarot P, Dumesnil JG. Prosthetic heart valves: selection of the optimal prosthesis and long-term management. Circulation. 2009;119:1034-48.
4. Masri A, Gillinov AM, Johnston DM, et al. Anticoagulation versus antiplatelet or no therapy in patients undergoing bioprosthetic valve implantation: A systematic review and meta-analysis. Heart. 2017;103:40-80.
5. Sasson L, Houry S, Raucher Shinfeld A, Cohen I, Lenczner O, Bove E et al. Right ventricular outflow tract strategies for

- repair of tetralogy of Fallot: Effect of monocusp valve reconstruction. *European Journal of Cardio-Thoracic Surgery*. 2012; 43(4):743-751.
6. Kumar M, Turrentine M, Rodefeld M, Bell T, Brown J. Right Ventricular Outflow Tract Reconstruction With a Polytetrafluoroethylene Monocusp Valve: A 20-Year Experience. *Semin Thorac Cardiovasc Surg*. 2016;28(2):463-470.
 7. Kahraman D. Trileaflet reconstruction of pulmonary valve for acute pulmonary valve insufficiency. *Turk Gogus Kalp Damar Cerrahisi Derg*. 2019;27(2):219-23
 8. Ozaki S, Kawase I, Yamashita H, Uchida S, Nozawa Y, Takatoh M, et al. A total of 404 cases of aortic valve reconstruction with glutaraldehyde-treated autologous pericardium. *J Thorac Cardiovasc Surg*. 2014;147(1):301–6.
 9. Baird CW, Cooney B, Chávez M, Sleeper LA, Marx GR, Del Nido PJ. Congenital aortic and truncal valve reconstruction using the Ozaki technique: Short-term clinical results. *J Thorac Cardiovasc Surg*. 2021;161(5):1567–77.
 10. Levine AJ, Miller PA, Stumper OS, Wright JG, Silove ED, De Giovanni J V, et al. Early results of right ventricular-pulmonary artery conduits in patients under 1 year of age. *Eur J cardio-thoracic Surg Off J Eur Assoc Cardio-thoracic Surg*. 2001;19(2): 122–6.
 11. Li X, Guo Y, Ziegler KR, Model LS, Eghbalieh SDD, Brenes RA, et al. Current usage and future directions for the bovine pericardial patch. *Ann Vasc Surg*. 2011;25(4):561–8.
 12. Baird C, Chávez M, Friedman K. Pulmonary Valve Reconstruction Using the Ozaki Leaflet Reconstructive Techniques. *Ann Thorac Surg*. 2021; 111(1):e19-e21.

© 2021 Dilawar et al.; This is an Open Access article distributed under the terms of the Creative Commons Attribution License (<http://creativecommons.org/licenses/by/4.0>), which permits unrestricted use, distribution, and reproduction in any medium, provided the original work is properly cited.

Peer-review history:

The peer review history for this paper can be accessed here:
<https://www.sdiarticle4.com/review-history/75385>