

# Recurrent Sigmoid Volvulus after Sigmoidectomy: 3 Clinical Cases

Murielle Etienne Julie Note Madzele<sup>1,2\*</sup>, Didace Massamba Miabaou<sup>1,2</sup>, Pierlesky Elion Ossibi<sup>1,2</sup>, Moïse Service Yanguedet<sup>1</sup>, Noé Henschel Motoula Latou<sup>1,2</sup>, Prude Pertinie Avala<sup>1</sup>, Giresse Bienvenu Tsouassa Wa Ngono<sup>1</sup>, Meddi Bhodého Monwongui<sup>1</sup>, Carmich Nzaka Moukala<sup>1</sup>

<sup>1</sup>Department of Digestive Surgery, University Hospital Center of Brazzaville, Brazzaville, Republic of the Congo

<sup>2</sup>Faculty of Health Sciences, Marien Ngouabi University, Brazzaville, Republic of the Congo

Email: \*murielle.note@yahoo.fr

**How to cite this paper:** Note Madzele, M.E.J., Massamba Miabaou, D., Elion Ossibi, P., Service Yanguedet, M., Motoula Latou, N.H., Avala, P.P., Tsouassa Wa Ngono, G.B., Bhodého Monwongui, M. and Nzaka Moukala, C. (2023) Recurrent Sigmoid Volvulus after Sigmoidectomy: 3 Clinical Cases. *Surgical Science*, 14, 712-719.

<https://doi.org/10.4236/ss.2023.1412077>

**Received:** November 10, 2023

**Accepted:** December 18, 2023

**Published:** December 21, 2023

Copyright © 2023 by author(s) and Scientific Research Publishing Inc. This work is licensed under the Creative Commons Attribution International License (CC BY 4.0).

<http://creativecommons.org/licenses/by/4.0/>



Open Access

## Abstract

**Introduction:** Recurrent sigmoid volvulus is a medical and surgical emergency. It is the recurrence of a twisting of the sigmoid loop around its mesenteric axis initiating an occlusion by strangulation. The risk factors of colonic volvulus are: a dolichosigmoid, a chronic constipation, a tumor, ...In Western countries, recurrences of sigmoid volvulus after surgery are rare and due to a non resection of a dolicho-megacolon. Most African studies do not report any recurrence of sigmoid volvulus after sigmoidectomy. This work aims to describe three original cases of recurrence of sigmoid volvulus after sigmoidectomy recorded at the University Hospital of Brazzaville and to analyze their causes and surgical management. **Clinical Observation:** We studied the cases of three male patients, whose average age was 73 years, each of them having a history of chronic constipation and sigmoidectomy for sigmoid volvulus with an average delay of recurrence of 5.3 years. They all underwent emergency laparotomy for acute intestinal obstruction on scarred abdomen. The surgery permitted to unfold a recurrent volvulus of the sigmoid associated with circumferential scar fibrosis on the volvulated sigmoid loop. A second colectomy was performed. The histological results of the surgical specimens were normal for two patients and revealed signs of tissue necrosis for the third patient. The postoperative outcome was without incident for two patients. The third patient died after developing a septic shock. **Conclusion:** Recurrent sigmoid volvulus after sigmoidectomy is rare. The etiological factors for our three patients were incomplete sigmoidectomy during the first operation and chronic constipation.

## Keywords

Recurrent Volvulus, Sigmoid, Sigmoidectomy

## 1. Introduction

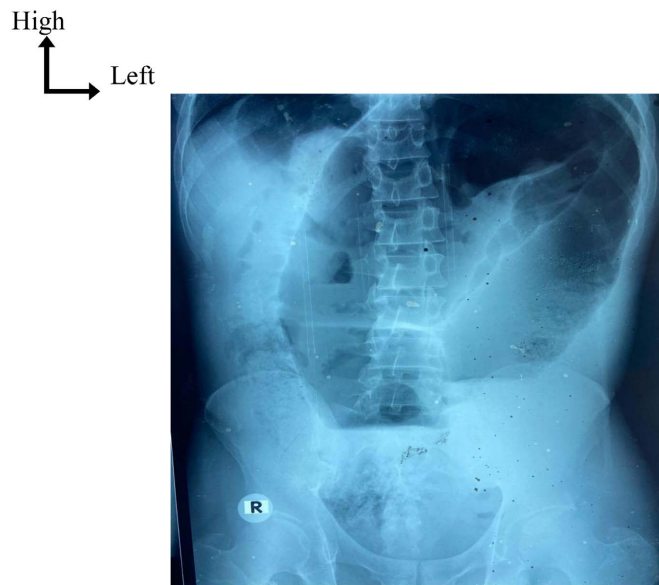
Recurrent sigmoid volvulus (RSV) is a medical and surgical emergency [1] [2]. It is the recurrence of a twisting of the sigmoid loop around its mesenteric axis causing a mechanical occlusion by strangulation [1] [3]. While the risk factors of sigmoid volvulus (SV) are numerous and well described in many studies (dolicho-megacolon, chronic constipation, intestinal tumor, etc.) [1] [4] [5] [6], the risk factors of recurrent forms after sigmoidectomy are still poorly documented in sub-Saharan Africa. In Western countries, some recurrences of an SV after surgery are described as related to a non operated dolichomegacolon during the initial surgery of the SV [7] [8].

In sub-Saharan Africa, sigmoidectomy, whether ideal or followed by a stoma, remains a therapeutic standard in centers where treatment by endoscopic devolvulation and exsufflation is not available [9] [10] [11]. In Congo indeed, in a 2005 study, Elé described the usual practice of surgery and non-endoscopic techniques as the main treatment of SV in emergency. No recurrence of volvulus was described post-sigmoidectomy [12]. Therefore, the present article presents three original cases of RSV post-sigmoidectomy treated at the University Hospital of Brazzaville, to raise awareness among hospital practitioners, of the potential risk of RSV among, to identify the main causes of recurrence and to detail the therapeutic carried out after the recurrence.

## 2. Clinical Observation

Three patients were recorded.

Patient 1, a 72 year-old male, was received in the surgical emergency room of the University Hospital of Brazzaville in March 2016 for acute abdominal pain of sudden onset predominating in the left flank and iliac fossa, cramp-like, not very intense, quickly associated with a cessation of stools and intestinal gas, then food vomiting. Symptoms had started approximately 24 hours prior to admission in the hospital. The patient had a history of chronic constipation and ideal sigmoidectomy for SV was performed in 2011. His general condition was good. He had a midline laparotomy scar above and below the umbilical, an abdominal distention and an asymmetrical tympanism. The bowel sounds were exaggerated. The rectal ampulla was empty. On the paraclinical level, the plain abdominal X-ray in frontal view, patient in standing position, showed a gaseous inverted U sign of the loop with a double air-fluid level (**Figure 1**). There was no abdominal CT scan performed. These clinical and radiological assessments strongly suggested acute intestinal obstruction due to colonic volvulus, which was the indication for surgical treatment. The pre-anesthetic laboratory assessment was normal. The patient was conditioned using 2 peripheral venous lines, a nasogastric tube and a urinary catheter for short-term preoperative intensive care. An emergency laparotomy under General anesthesia was performed on the day of the patient's admission. The laparotomy led to the discovery of a volvulus of the mesenteric axial sigmoid without intestinal distress. We particularly noted the presence of circumferential scar fibrosis on the volvulated loop, at approximately 25 cm

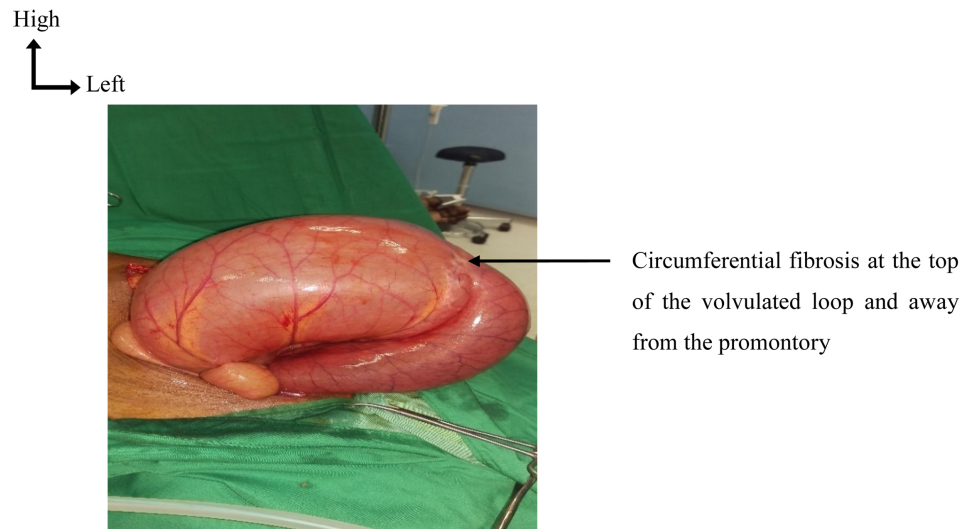


**Figure 1.** Photo of standard plain abdomen X-ray (front, standing). Image of a gaseous inverted U sign of the loop with a double air-fluid level. Source: Brazzaville University Hospital.

from the intestinal area facing the promontory (**Figure 2**). The performed surgical procedure was an ideal sigmoidectomy. The postoperative outcome without incident, allowing the patient to be discharged on the 9th postoperative day. The histological analysis of the surgical sample was normal.

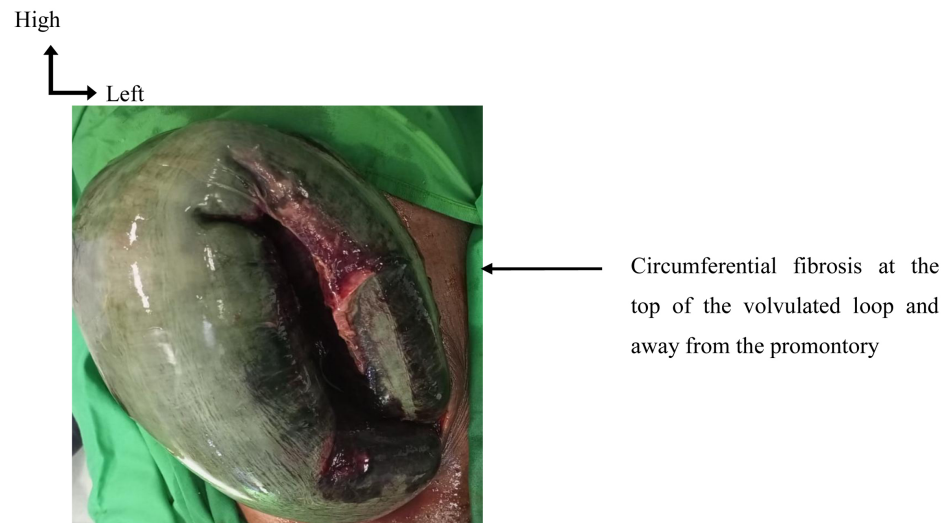
Patient 2, was a 78 year-old male, admitted to the surgical emergency room of the University Hospital of Brazzaville in July 2018 for symptoms similar to those of patient 1 ongoing for approximately 48 hours with a period of spontaneous resolution of a few hours preceding the intense resurgence of abdominal pain. The patient 2 had a history of chronic constipation and ideal sigmoidectomy for SV, performed in 2013. The clinical examination was similar to patient 1 apart from the presence of pasty stools in the rectal ampulla. The plain X-ray of the abdomen in frontal view and in a standing position revealed a gaseous inverted U sign of the loop with a double air-fluid level. No abdominal CT scan was performed. The diagnosis of intestinal obstruction by colonic volvulus was retained with an indication of laparotomy under General anesthesia. After a normal pre-anesthetic assessment and conditioning, the patient was admitted in emergency to the operating theater approximately 5 hours after arrival. The surgery exploration highlighted the presence of a volvulus of the mesenteric axial sigmoid associated with scar fibrosis on the volvulated loop. The intestinal loop was viable. The patient underwent an ideal sigmoidectomy with a positive postoperative outcome. He was discharged eight days after surgery. The histological analysis of the surgical specimen was normal.

Patient 3, was a 69 year-old male admitted in the surgical emergency room of the University Hospital of Brazzaville in February 2020 for a sudden onset of acute abdominal twisting pain lasting for 72 hours, localized in the left iliac fossa



**Figure 2.** Surgery exploration of patient 1. Recurrent volvulus of the sigmoid with circumferential scar fibrosis at the top of the volvulated loop, away from promontory area. Viable loop. Source: Brazzaville University Hospital.

then generalized, intense, not relenting after administration of analgesics and antispasmodics. The pain was associated with food vomiting turning to fecaloid vomiting, a cessation of stools and gas and a fever that started a few hours before admission. He had a history of chronic constipation, chronic renal failure and prostate adenocarcinoma in complete remission after radiotherapy. He underwent a sigmoidectomy followed by a colostomy for SV in July 2014. The restoration of digestive continuity was achieved in September 2014. At the admission, the patient presented an altered general condition with moderate dehydration and fever. He had 2 surgical scars, one in the middle, above and below the umbilical; and the other oblique on the left flank. There was a global abdominal distension, a muscular defense and tympany mainly found in the left part of the abdomen. The bowel sounds were exaggerated and the rectal ampulla was empty. The standard plain abdominal X-ray revealed the pathognomonic horse-shoe sign of intestinal volvulus. The patient did not benefit from an abdominal CT scan. Thus, the diagnosis of colonic volvulus was made. For the purpose of performing a laparotomy, a pre-anesthetic assessment revealed a neutrophilic leukocytosis at  $18 \times 10^3/\text{mm}^3$  and elevated serum creatinine of 38 mg/l. The rest of the laboratory routine was normal. After conditioning and short-term intensive care, the patient was taken into the operating theater. The laparotomy revealed a volvulus of the mesenteric-axial sigmoid complicated by extensive necrosis of the loop overlying the strangulation zone (**Figure 3**) associated with a mild effusion of suspicious liquid sampled for laboratory analysis. The procedure performed was a sigmoidectomy removing the entire necrotic portion, followed by a Hartmann-type colostomy. During the surgery, a complication occurred involving an accidental colonic perforations with spillage of stools into the peritoneal cavity during the manoeuvre of resection. Consequently, before abdominal closure, an abundant peritoneal washing with physiological saline was



**Figure 3.** Surgery exploration of patient 3. Recurrent sigmoid volvulus. Necrotic loop. Source: Brazzaville University Hospital.

performed, then a drain was placed in the peritoneal cavity. Before, during and after the procedure, a medical treatment including a probabilistic and broad-spectrum antibiotherapy was dispensed to the patient. The antibiotics combined a third generation of cephalosporins and an imidazole. The post-operative outcome was aggravated by a severe sepsis and unfortunately the patient died on the second day after surgery. The histological analysis of the surgical specimen revealed an extensive colonic intestinal necrosis and 3 perforations.

In short, the three patients were men, with an average age of 73 years old. They all had a history of sigmoidectomy for SV. The average delay of recurrence after sigmoidectomy was of 5.3 years. They all had a history of chronic constipation as well. All patients underwent emergency surgery and laparotomy. A SV was discovered. The clear mark of scar fibrosis was visible on the volvulated loop and far from the promontory area for all patients. The volvulus was complicated by necrosis for the patient 3. An ideal sigmoidectomy was performed in 2 patients; while the 3rd underwent a sigmoidectomy followed by a colostomy. The average hospitalization length was 6.3 days.

### 3. Discussion

From an epidemiological point of view, the frequency of SV is higher in developing countries, where its incidence may reach 50% of intestinal obstructions [9] [10]. In Western countries, SV is rather an exceptional cause of low occlusion after colonic cancers and sigmoid diverticula [4].

SV is considered a pathology of males in their sixties and seventies [10] [13] [14] as for our patients. However, in our cases, it is a recurrent form after a sigmoidectomy. This entity is little reported in the Medical literature globally and even less in Sub Saharan literature. The small number of cases reported in our context could be explained by the fact that many patients might have been operated in rural areas or in private clinics by practitioners who do not report them.

Furthermore, our records reveal that some patients died preoperatively following an occlusion on a scarred abdomen without a precise diagnosis.

Regarding the delay of occurrence of a SV after sigmoidectomy, it varies from 2 to 6 years in some studies [15] which is similar to the delays of our patients which was 5.3 years on average.

When the diagnosis is established, the treatment is a medical and surgical emergency [1] [2]. Note that unless ischemia or colonic perforation is suspected, emergency endoscopic treatment of this pathology is recommended. This treatment consists of carrying out a detorsion by sigmoidoscopy followed by a colon, exsufflation then a colonic wash-aspiration. The endoscopic procedure will precede a sigmoid resection with or without anastomosis by laparotomy or laparoscopy in delayed emergency. This procedure is described by several authors [16] [17] [18] [19] and validated by consensus in 2023 by the World Society for Surgical Emergencies [2]. In that regard, it is admitted that recurrences are more frequent after conservative treatments [18]; but they can also occur after an incomplete sigmoidectomy or in cases of megacolon, hence the interest in an enlarged or subtotal colectomy in cases of associated dolichocolon [19].

In the Republic of Congo, the emergency procedure by laparotomy is based on the ideal sigmoidectomy or on sigmoidectomy followed by a colostomy according to Hartmann or according to Bouilly Volkmann. In some cases of dolichocolon, sigmoidectomy can be extended to colectomy [12]. In our three cases, we observed colonic distension with the presence of circumferential scar fibrosis on the volvulated loop, which we linked to the scar of the anterior anastomosis. This scar, due to its position, demonstrated an old colocolonic anastomosis rather than colorectal anastomosis if a total sigmoidectomy had been performed. Therefore several hypotheses explain the recurrence of volvulus in our patients:

- first, we assume that the previous sigmoidectomy was not total and the remaining part of the sigmoid was therefore responsible for the recurrent volvulus: the same causes produce the same effects. On this subject, we believe that to avoid these recurrences, it is better to perform a total sigmoidectomy or even a left colectomy in cases of dolichocolon. If a colostomy is performed, the time to reestablish digestive continuity should allow to complete the sigmoidectomy if it was initially incomplete [11].
- then, all patients had a history of chronic constipation. This suggests that chronic constipation in a scarred abdomen may be a risk factor of recurrence of volvulus even after sigmoidectomy. This hypothesis is supported by the study by Ba and al [9] who found that 30% of patients operated for SV presented chronic constipation. Indeed, a chronic constipation, a history of abdominal surgery but also of pregnancy, a mega dolichocolon and a prolonged use of certain psychotropic medications have been identified as main risk factors of colonic volvulus [18]-[22]. Thus, in order to prevent SV in general and after sigmoidectomy in particular, it is of great importance to treat the chronic constipation of adults.

Regarding the therapeutic attitude, it should be noted that in our country as in sub-Saharan Africa in general [11] [12] [13] [14], the technical platform and medical expertise do not systematically allow the recommendations of the World Association of Surgical Emergencies [2]. Thus, in an emergency, and in our context, treatment generally consists of performing an ideal open sigmoidectomy or followed by a colostomy.

#### 4. Conclusion

RSV after sigmoidectomy is rare and little described in the literature. The etiological factors noted in our three patients were an initially incomplete sigmoidectomy and chronic constipation. Therefore, in order to protect patients from a recurrence of sigmoid volvulus, any sigmoidectomy must be total. When volvulus occurs in a dolicho-megacolon, a left colectomy can be performed. In the case where a stoma is created, the time taken to reestablish colonic continuity should allow the excision of the sigmoid to be completed. Added to this is the correct treatment of chronic constipation in adults.

#### Consent for Publication

The patients' families kindly consented to the use of their medical records for publication.

#### Conflicts of Interest

The authors declare no conflicts of interest.

#### References

- [1] Basato, S., Fui, S.L.S., Pautrat, K., Tresallet, C. and Pocard, M. (2014) Comparaison pour le traitement chirurgical du volvulus du sigmoïde de deux techniques, coelioscopie versus voie élektive. *Journal de Chirurgie Viscérale*, **151**, 444-448. <https://doi.org/10.1016/j.jchirv.2014.07.009>
- [2] Tian, B.W.C.A., Vigutto, G., Tan, E., van Goor, H., Bendinelli, C., Abu-Zidan, F., *et al.* (2023) WSES Consensus Guidelines on Sigmoid Volvulus Management. *World Journal of Emergency Surgery*, **18**, Article No. 34. <https://doi.org/10.1186/s13017-023-00502-x>
- [3] Fo, Y., Kang, X., Tang, Y. and Zhao, L. (2023) Analysis of Clinical Diagnosis and Treatment of Intestinal Volvulus. *BMC Gastroenterology*, **23**, Article No. 93. <https://doi.org/10.1186/s12876-023-02699-2>
- [4] Abdelrahim, A., Zeidan, S., Qulaghassi, M., Ali, O. and Boshnaq, M. (2022) Dilemma of Sigmoid Volvulus Management. *The Annals of the Royal College of Surgeons of England*, **104**, 95-99. <https://doi.org/10.1308/rcsann.2021.0123>
- [5] Raahave, D. (2018) Dolichocolon Revisited: An Inborn Anatomic Variant with Redundancies Causing Constipation and Volvulus. *World Journal of Gastrointestinal Surgery*, **10**, 6-12. <https://doi.org/10.4240/wjgs.v10.i2.6>
- [6] Bayeh, A.B. and Abegaz, B.A. (2021) The Role of Sigmoid Colon Anatomic Dimensions in the Development of Sigmoid Volvulus, North-Western Ethiopia. *PLOS ONE*, **16**, e0260708. <https://doi.org/10.1371/journal.pone.0260708>

- [7] Morrissey, T.B. and Deitch, E.A. (1994) Recurrence of Sigmoid Volvulus after Surgical Intervention. *The American Surgeon*, **60**, 329-331.
- [8] Chung, Y.F., Eu, K.W., Nyam, D.C., Leong, A.F., Ho, Y.H. and Seow-Choen, F. (1999) Minimizing Recurrence after Sigmoid Volvulus. *British Journal of Surgery*, **86**, 231-233. <https://doi.org/10.1046/j.1365-2168.1999.01034.x>
- [9] Ba, P., Diop, B. and Soumah, S. (2015) Prise en charge du volvulus du côlon sigmoïde en milieu tropical à Thiès (Sénégal). *Médecine et Santé Tropicales*, **25**, 316-318. <https://doi.org/10.1684/mst.2015.0476>
- [10] Ouchemi, C., Moussa, A. and Moussa, K. (2015) Résultats du traitement du volvulus du sigmoïde à N'djamena, Tchad. *European Scientific Journal*, **11**, 245-253.
- [11] Traoré, D., Coulibaly, B., Togola, B., Bengaly, B., Mariko, Y., Traoré, I., *et al.* (2013) Volvulus du colon sigmoïde: Traitement chirurgical et pronostic dans les services de chirurgie générale du CHU du Point G. *Le Mali Médical*, **3**, 15-19.
- [12] Elé, N., Okiémy, G., Koutaba, E., Diabakana, F.M., Chocolat, R., Ibamba Ikassi, A., Note Madzele, M., Datsé, Y. and Massengo, R. (2005) Traitement chirurgical en urgence du volvulus du côlon pelvien à Brazzaville. *Bulletin Médical d'Owendo*, **10**, 40-44.
- [13] Kambiré, J.L., Ouédraogo, S., Ouédraogo, B., Béré, B. and Zida, M. (2021) Le volvulus du côlon sigmoïde: À propos de 55 cas pris en charge au Centre Hospitalier Universitaire de Ouahigouya, Burkina Faso. *Revue Africaine de Chirurgie et Spécialités*, **1**, 11-16.
- [14] Ghariani, B., Houissa, H. and Sebai, F. (2010) Prise en charge du volvulus du sigmoïde. *La Tunisie Médicale*, **88**, 163-167.
- [15] Atamanalp, S.S. and Ozturk, G. (2011) Sigmoid Volvulus in the Elderly: Outcomes of a 43-Year, 453-Patient Experience. *Surgery Today*, **41**, 514-519. <https://doi.org/10.1007/s00595-010-4317-x>
- [16] Rothmann, C., Pierrard, O. and Schmutz, T. (2018) Volvulus du sigmoïde: Diagnostic et traitement en urgence. *Journal Européen des Urgences et de Réanimation*, **30**, 41-45. <https://doi.org/10.1016/j.jeurea.2018.01.001>
- [17] Bruzzi, M., Voron, T. and Douard, R. (2016) Prise en charge du volvulus du sigmoïde. *Hépatogastro & Oncologie Digestive*, **10**, 1005-1013.
- [18] Korkut, E., Peksoz, R., Disci, E. and Atamanalp, S.S. (2023) Factors Affecting Recurrence in Sigmoid Volvulus. *Pakistan Journal of Medical Sciences*, **39**, 150-153. <https://doi.org/10.12669/pjms.39.1.6882>
- [19] Tan, K.K., Chong, C.S. and Sim, R. (2010) Management of Acute Sigmoid Volvulus: An Institution's Experience over 9 Years. *World Journal of Surgery*, **34**, 1943-1948. <https://doi.org/10.1007/s00268-010-0563-8>
- [20] Sozen, S., Das, K., Erdem, H., Menekse, E., Cetinkunar, S. and Karateke, F. (2012) Resection and Primary Anastomosis with Modified Blow-Hole Colostomy or Hartmann's Procedure. Which Method Should Be Performed for Gangrenous Sigmoid Volvulus? *Chirurgia*, **107**, 751-755.
- [21] Cortez, N., Berzosa, M., Muddasani, K. and Ben-David, K. (2020) Endoscopic Decompression of Recurrent Sigmoid Volvulus in Pregnancy. *Journal of Investigative Medicine High Impact Case Reports*, **8**, 1-3. <https://doi.org/10.1177/2324709620975939>
- [22] Elé, N., Nzaka, M.C.D., Massamba Miabaou, D., Note Madzele, M., Motoula, L.N. and Kébélé, F. (2014) Volvulus du sigmoïde au cours de la grossesse: Cas clinique et revue de la littérature. *Journal Africain de Chirurgie Digestive*, **14**, 1662-1665.