



## Maxillary Secondary Impression in Case of Hyperplastic Schroder Area: Clinical Report

Masmoudi Karim<sup>1\*</sup>, Jemli Safa<sup>1</sup>, Achraf Fnaiech<sup>1</sup> and Adouani Hana<sup>1</sup>

<sup>1</sup>Department of Removable Prosthetics, LR12ES11 Laboratory, Faculty of Dental Medicine, University of Monastir, Tunisia.

### **Authors' contributions**

*This work was carried out in collaboration among all authors. Author MK designed the study, performed the case report, wrote the protocol and wrote the first draft of the manuscript. Authors JS and AF managed the discussion. Author AH managed the literature searches. All authors read and approved the final manuscript.*

### **Article Information**

#### Editor(s):

(1) Dr. Ketij Mehulić, University of Zagreb, Hospital Center Zagreb, Croatia.

#### Reviewers:

(1) Anahita Punj, Kalaoji Narayana Rao University of Health Sciences, India.

(2) Mona Ionaş, University Lucian Blaga of Sibiu, Romania.

Complete Peer review History: <http://www.sdiarticle4.com/review-history/56492>

**Received 20 February 2020**

**Accepted 26 April 2020**

**Published 02 May 2020**

**Case Study**

### **ABSTRACT**

Much has been spoken about secondary impression in making complete denture. In fact, it must exploit all the positive landmarks enhancing the stability.

Generally, an immediate recording of the denture support area is possible while the fibromucosa is adherent and firm, but uncommonly, due to anatomical particularities such as hyperplastic Schroder area, the impression requires specific technical modifications.

Indeed, this glandular zone, defined as an overextended non-inflammatory palatal papillary hyperplasia require an impression using selective pressure technique while the surgical option is impractical.

The aim of this paper is to explain the principles of this method through a case report and detail the clinical steps of the denture fabrication enhancing the comfort and the fit of the prosthetic rehabilitation.

*Keywords: Retention; complete denture; impression; hyperplasia.*

\*Corresponding author: Email: maskar79.mk@gmail.com;

## 1. INTRODUCTION

Maxillary hard palate is usually covered by a firm and adherent fibro-mucosa acting as stress-bearing tissue and should be considered as positive anatomical landmark [1]. When it is overgrown, SCHROEDER area extends from the first molar region to the soft palate. Structurally, it is rich of glandular and adipose tissues, therefore, its compressibility depends on its thickness and mobility [2].

Schroeder area (S.A.) overgrowth is extremely unusual and could be confused with inflammatory papillary hyperplasia. The latter is associated with ill-fitting dentures and yeast colonization [3].

So far, this mucosa abnormality could be distorted during the impression. Boucher described a selective-pressure impression technique providing improved palatal adaptation of the definitive denture base [4].

This article reviews the different steps of achieving the custom tray design relieving S.A. while taking secondary impression.

## 2. CLINICAL CASE PRESENTATION

A 62-year-old man, with no medical history, presented to the department of prosthodontics, faculty of dentistry Monastir, Tunisia requesting a complete prosthetic rehabilitation. Clinical investigation revealed that he has been edentulous since 3 years with no history of denture wearing. Intraoral examination showed

high bony maxillary ridge and numerous hyperplastic light pink nodules up to 6 mm in their greatest dimension exclusively involving the hard palate and reaching the limit of the soft one (Fig. 1). On t-burnisher palpation, nodules were soft, fluctuant and mobile.

Anatomical pathology underlines the typical aspect of normal mucosa; no inflammation was detected.

After comprehensive observations, secondary impression should be taken using selective pressure technique: The steps are described in details in the following subsections.

### 2.1 Preliminary Impression

The maxillary preliminary impression was made using irreversible hydrocolloid. This negative record was meticulously taken so that compression was minimized: No major pressure spots were found. The impression was quickly poured (Fig. 2).

### 2.2 Custom Tray Fabrication

The floating S.A. is perfectly defined by the clinician; the delineation is performed by palpation and scribed on the cast (Fig. 3).

The redundant tissue was blocked out by flowing a 3 mm thick layer of modeling wax over the outlined area. The separating medium was applied with a brush to avoid the special tray from bonding to the cast (Fig. 4).

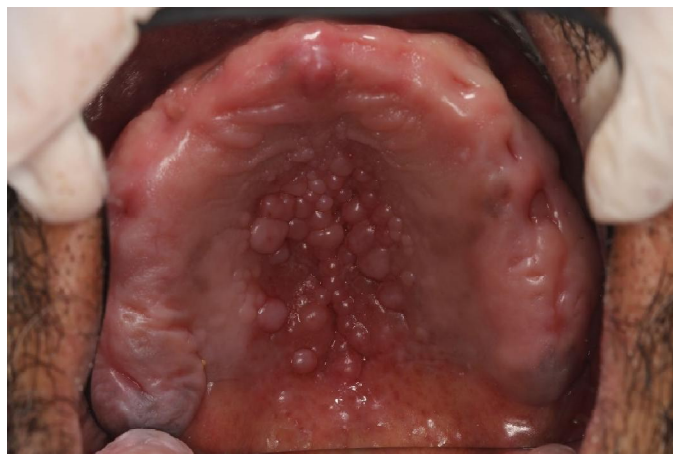
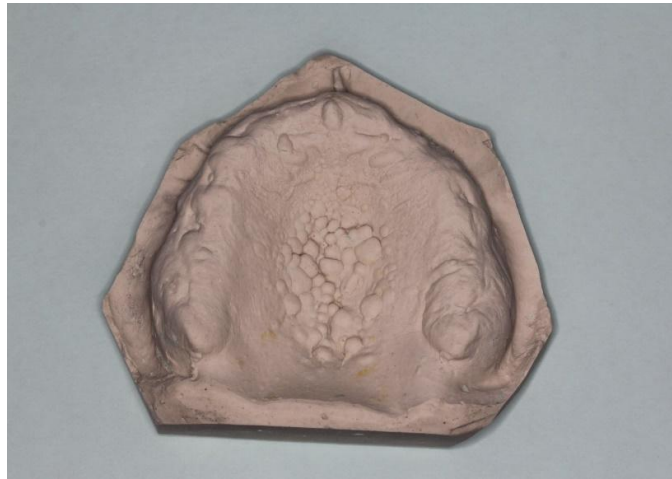
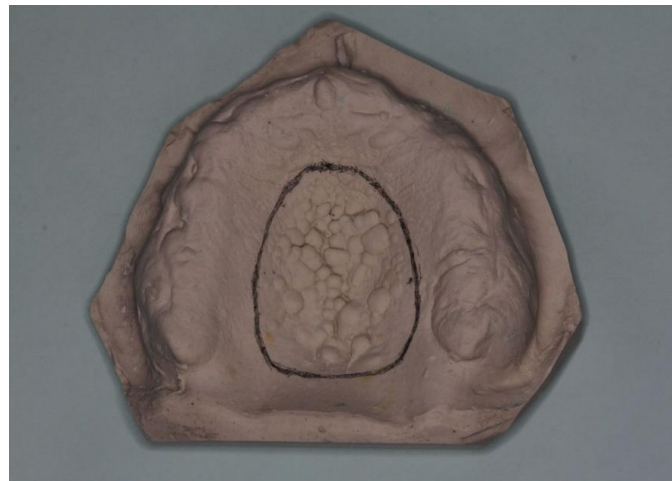Fig. 1. Hyperplastic Schroeder zone



**Fig. 2. Overview of the primary cast**



**Fig. 3. In black: The boundaries of the area to space**

The special tray was made using self-curing resin by mixing 3:1 powder to liquid. At the dough stage of the polymerization, the material was kneaded in the hand to achieve a homogeneous mix, and then it was shaped in 2 mm-thickness and adapted over the cast from the center to the periphery. The excess was cut with blade before the resin had set.

After the exothermic reaction, the acrylic resin tray was removed from the preliminary cast. The over-extensions were trimmed with an acrylic bur, the edges were 2 mm thick and smoothly rounded. Finally, border molding was made using green low fusing compound softened in water bath and kneaded with fingers to improve qualities (Figs. 5,6).

### **2.3 Occlusion Record and Final Impression**

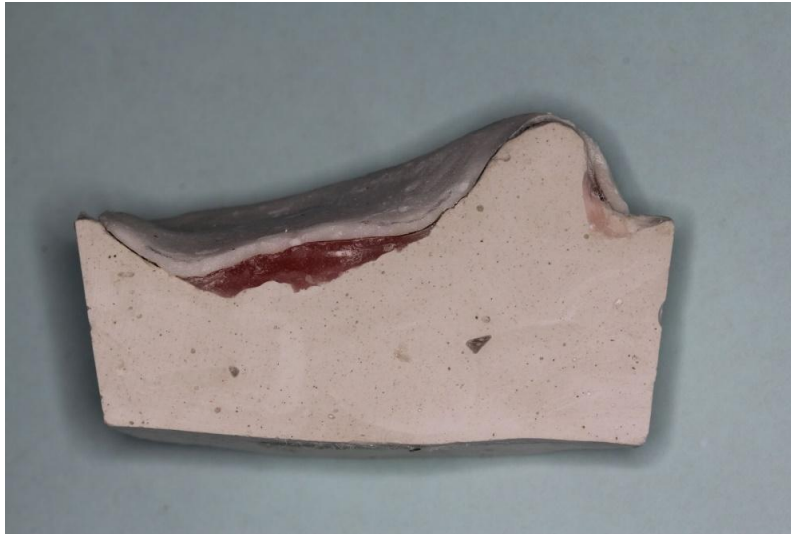Two occlusion rims were contoured and adjusted. The upper occlusal rim represented approximately the length of the natural anterior teeth, the incisal plane was parallel with interpapillary line. Occlusal plane was roughly parallel to the ala-tragus line. According to Buchman's technique, the Lower occlusal rim was used to record the preliminary centric relation throughout the act of swallowing, the occlusal vertical dimension measurement was repeated three times then the average was calculated (Fig. 7).

After testing the retention, holes were drilled into the palate of the custom tray with a round bur to

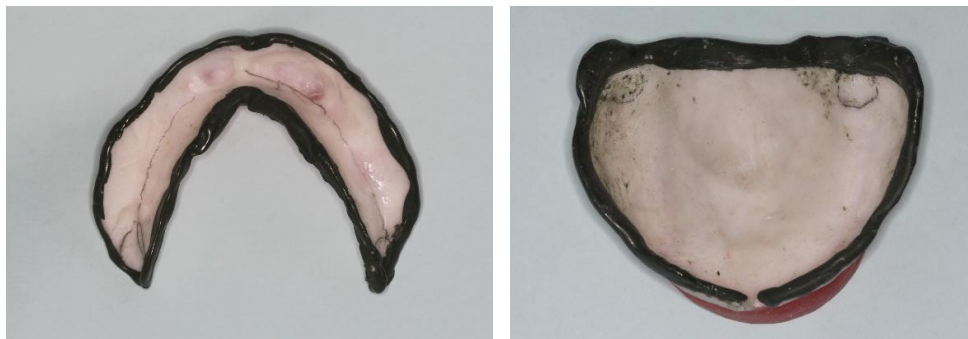remove the excess of impression material (Fig. 8).

The mixed impression polysulfide was placed on the tray with borders covered and inserted in the

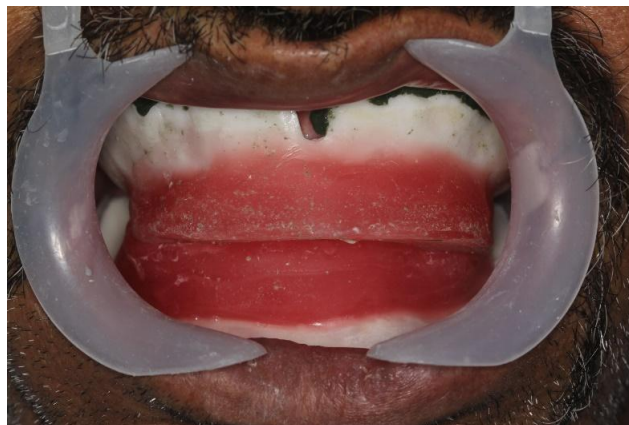mouth, no excess of material was loaded. Finally, the impression was taken using the occlusal pressure; The patient was gently guided to centric relation at the correct vertical occlusal dimension until the material sets (Figs. 9, 10).



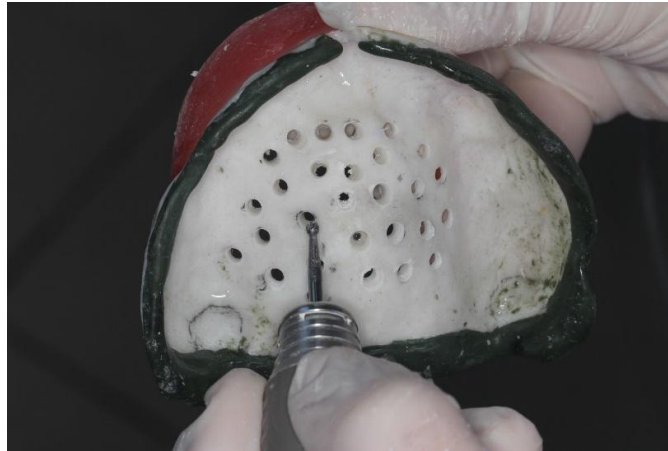
**Fig. 4. The thickness of the spacer is about 3 mm**



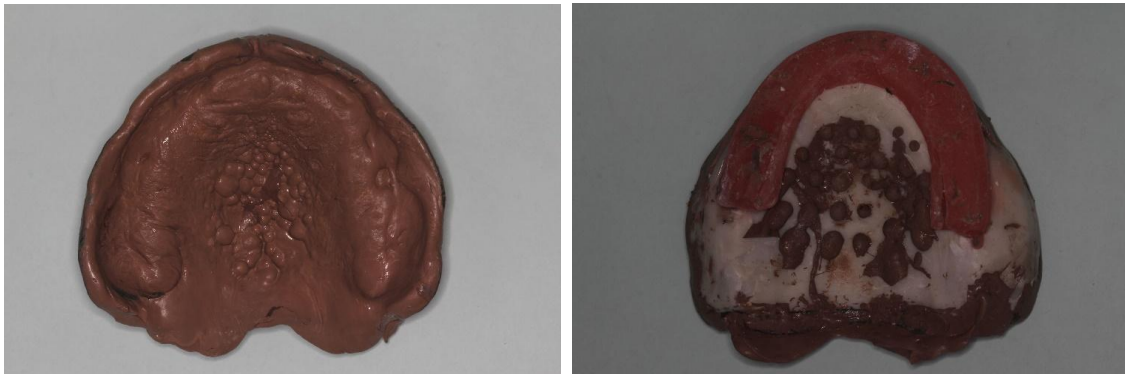
**Figs. 5 and 6. The extensions are well defined: Border molding should be smooth and rounded**



**Fig. 7. Centric occlusion record**




**Fig. 8. Holes windows and wax spacer reduce the hydraulic pressure and minimize tissue displacement**



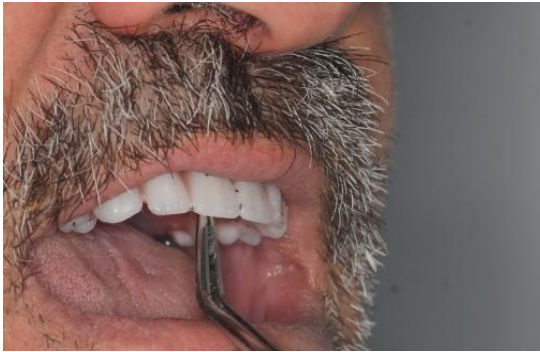**Figs. 9 and 10. Smooth well defined peripheries and maximum extension, the impression has no pressure spot**

Artificial teeth were set according to balanced occlusal arrangement in order to preserve the stability of the dentures. After the polymerization, all the errors of static and dynamic occlusion were corrected by laboratory remount and occlusal equilibration (Figs. 11, 12).

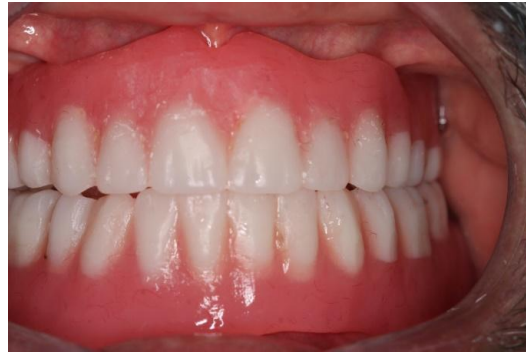During the adjustment appointment, retention and stability were checked (Fig. 13) and discomfort zones were removed. Both dentures borders should rest short of the functional sulcus depth to prevent dislodgement during function (Fig. 14).



**Figs. 11 and 12. Dentures equilibration using semi-adjustable articulator**



**Fig. 13. Applying a tipping force on the incisors in attempt to break the seal**



**Fig. 14. As the denture were seated, the labial frenum and flange extensions were checked**

### 3. DISCUSSION

Making impressions in complete denture treatment is of great importance, not only for dental retention and stability but also for the mucosa status which should be kept without any distortions.

Literature reveals that deglutition and mastication load should be maximum on primary stress bearing areas and in accordance with the histology of underlying tissue [5].

Adequate impression technique and material should be chosen in order to accurately record these structures with minimal compression of the tissues.

The mucosa of the S.A. of the patient was with different thickness and mobility; the distortion of this superficial area of non-adherent soft tissue leads to significant problem of stability.

Alleviating the pressure from the SA while taking the second impression is required in selective pressure technique [6].

The pressure applied while taking impression should fit the compressibility of the underlying tissues, it is possible due to the viscosity of the material used during the impression procedure in one hand, and to the applied load due to the contact between the tray and the oral tissues in another hand.

The overpressure applied during the impression procedure is reduced thanks to the presence of escape holes in the tray. The material flows ending up in a thin film with a minimal pressure over soft tissues [7].

In fact, physiological registration of the attached and unattached tissue reduces pressure on displaceable tissue which cannot support the denture, while it remains mucocompressive in hard zone.

Standard mucocompressive impression techniques are likely to result in an unretentive and unstable denture as this latter will be constructed on a model of the flabby tissue in a distorted state.

In the other hand, designing a prosthetic base largely spaced out facing the S.A. results in its expansion and volume augmentation by aspiration effect [8].

Finally, after the delivery, regular maintenance appointment is capital for every successfully hyperplasia managed case [9].

### 4. CONCLUSION

Based on the evaluation of the patient's satisfaction after two months of the appointment delivery, the fabrication of the prosthesis was a success despite of the maxillary anatomy conditions.

Commodiously, secondary impression should be taken with selective pressure technique which requires the use of custom tray which is spaced out adequate to the floating nodules and adapted to the adhering mucosa. This technique results in stable and retentive denture.

### CONSENT AND ETHICAL APPROVAL

As per international standard guideline participant consent and ethical approval has been collected and preserved by the authors.

## COMPETING INTERESTS

Authors have declared that no competing interests exist.

## REFERENCES

1. Limpuangthip N, Somkotra T, Arksornnukit M. Impacts of denture retention and stability on oral health-related quality of life, general health and happiness in elderly thais. *Curr Gerontol Geriatr Res*. 2019;2019:3830267. DOI: 10.1155/2019/3830267 eCollection 2019
2. Pierre Le Bars, Gaston Niagha, Ayepa Alain Kouadio, Julien Demoersman, Elisabeth Roy, Valérie Armengol, Assem Soueidan. Pilot study of laser doppler measurement of flow variability in the microcirculation of the palatal mucosa. *BioMed Research International*. 2016;7. Article ID: 5749150.
3. Sebaa S, Faltot M, De Breucker S, Boucherit-Otmani Z, Bafort F, Perraudin JP, Courtois P. *Ex vivo* decontamination of yeast-colonized dentures by iodine-thiocyanate complexes. *Clin Cosmet Investig Dent*. 2018;10:149-158.
4. Judson C. Hickey, George A. Zarb. Boucher's prosthodontic treatment for edentulous patients. Eighth Edition P.201.
5. Rubina Bansal, Manjit Kumar, Rashim Garg, Rishi Saini, Shaveta Kaushala. Prosthodontic rehabilitation of patient with flabby ridges with different impression techniques. *Indian J. Dent*. 2014;5(2):110-113.
6. Chopra S, Gupta NK, Tandan A, Dwivedi R, Gupta S, Agarwal G. Comparative evaluation of pressure generated on a simulated maxillary oral analog by impression materials in custom trays of different spacer designs: An *in vitro* study. *Contemp Clin Dent*. 2016;7(1):55-60. DOI: 10.4103/0976-237X.177108
7. Duncan JP, Raghavendra S, Taylor TD. A selective-pressure impression technique for the edentulous maxilla. *J Prosthet Dent*. 2004;92(3):299-301.
8. Tripathi A, Singh SV, Aggarwal H, Gupta A. Effect of mucostatic and selective pressure impression techniques on residual ridge resorption in individuals with different bone mineral densities: A prospective clinical pilot study. *J Prosthet Dent*. 2019;121(1):90-94. DOI: 10.1016/j.prosdent.2018.02.016 Epub 2018 Jul 10
9. Patel J, Jablonski RY, Morrow LA. Complete dentures: An update on clinical assessment and management: Part 1. *British Dental Journal*. Advance Online Publication, October 19, 2018.

© 2020 Karim et al.; This is an Open Access article distributed under the terms of the Creative Commons Attribution License (<http://creativecommons.org/licenses/by/4.0>), which permits unrestricted use, distribution, and reproduction in any medium, provided the original work is properly cited.

Peer-review history:

The peer review history for this paper can be accessed here:  
<http://www.sdiarticle4.com/review-history/56492>