



Surgical Management of Class III Skeletal

Ouassime Kerdoud^{1*} and Faïçal Slimani^{1,2}

¹*Service de Stomatologie et Chirurgie Maxillofaciale, Hôpital 20 Août CHUIBN ROCHD de Casablanca Royaume du Maroc, Morocco.*

²*Faculté de Médecine et de Pharmacie de Casablanca, Royaume du Maroc, Morocco.*

Authors' contributions

This work was carried out in collaboration between both authors. Author OK designed the study, wrote the first draft of the manuscript and managed the literature searches. Both authors read and approved the final manuscript.

Article Information

Editor(s):

(1) Dr. Franco Ferrante, University of Genoa, Italy.

Reviewers:

(1) Bruno Chrcanovic, Malmö University, Sweden.

(2) Jaswinder Kaur, Maharishi Markandeshwar University (MMDU), India.

(3) Alessia Paganelli, University of Modena and Reggio Emilia, Italy.

Complete Peer review History: <http://www.sdiarticle4.com/review-history/63700>

Case Study

Received 10 October 2020
Accepted 15 December 2020
Published 26 December 2020

ABSTRACT

The orthognathic surgery is a surgical manipulation of the facial skeleton to achieve normal anatomy and functions. This paper presents a case of a Class III skeleton treated using a surgical approach (Maxillary advancement surgery & mandibular setback) after 18 months of orthodontic preparation, the patient underwent a bimaxillary osteotomy. The aesthetic and functional result was satisfactory.

Keywords: Orthognathic surgery; class iii; sagittal osteotomy; skeletal deformit; lefort osteotomy.

1. INTRODUCTION

Skeletal class III is defined as a dysmorphose characterized by an abnormal position of the mandible and/or maxilla bone [1]. The skeletal deformity lead to abnormal position and malposition of teeth: the up incisors are in

labioversion beside the lower incisors are in linguoversion [2,3]. The surgical backward movement of the mandible must take into account the upper airway. Many researches have reported that Asian races have a higher prevalence of Angle Class III malocclusion than other races [4]. In our knowledge, many articles

*Corresponding author: E-mail: wassim.kdd@gmail.com;

published in skeletal class III do not focus on the early surgical management of skeletal class III in a critical age at mid- or late-growth, which is the case of our case-report. The authors try to emphasize the benefit of early treatment (even at the end or mid of growth).

2. CASE REPORT

A 17-year-old child was complaining of difficulty in chewing with no general history.

2.1 Clinical Evaluation

Examination revealed a long, symmetrical face, a concave profile, maxillary deficiency with mandibular excess and incompetent lips with a protruding lower lip. In the vertical direction, the lower third part of the face is larger than the others parts.

Intraoral examination showed a good oral hygiene, complete anterior crossbite with overjet

and wide anterior open bite of 5 mm, skeletal class III type deformities; the maximum mouth opening was 36 mm. Excursion and protrusive movements were not restricted. Speech difficulties and labial incompetence were also noted clinically.

The panorex showed an absence of tooth 21 without bone resorption, normal mandibular condyles and no signs or symptoms of craniomandibular dysfunction.

Teleradiography lateral view, showing maxillary deficiency and mandibular protrusion.

The scintigraphy (Technetium 99m pyrophosphate) was made, showing the absence of a blastic lesion or increasing growth activity.

2.2 Pre-Surgical Time

Preoperative explanation of hospitalization, surgery and cares to parents was done.

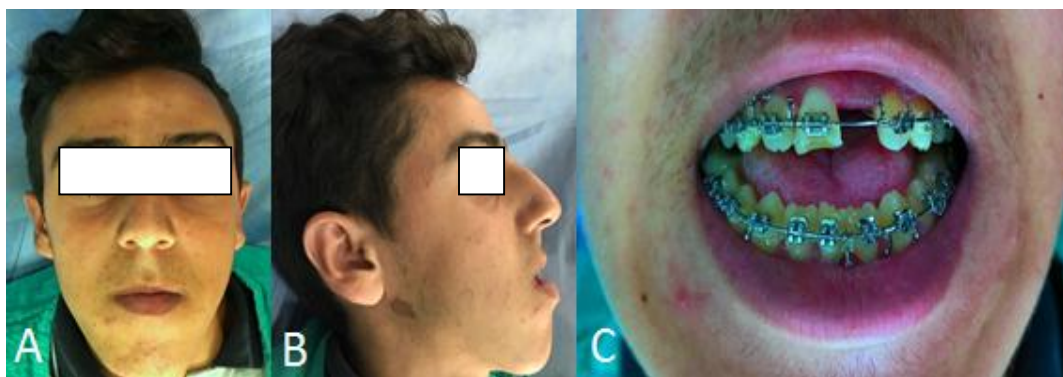


Fig. 1. A 17-year-old child (A) front view (B) profile view (C) crossbite & openbite

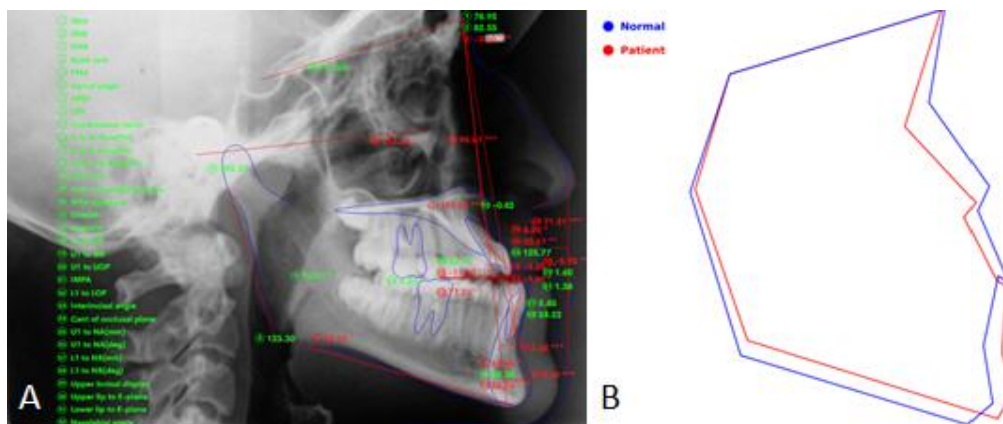


Fig. 2. Cephalometric analysis (A) The treatment goals (B)

The treatment's objectives were: the crossbite correction, surgical correction of the transverse dimension, correct lip profile, and incompetence, Achieve optimal functional occlusion. A pre-surgery diagnostic of skeletal deformities was made based on the clinical examination and radiologic studies.

The cephalometric values are shown in Table 1.

2.2.1 Initial assessment

- **Skeletal**

- Skeletal Class III (severe)
Maxilla: Normal
Mandible: Protrusion (moderate)
Chin point: Protrusion (severe)
- Normodivergent (mesocephalic) facial pattern

- **Dental**

- Class III molar relationship (severe)
- Overjet: Anterior crossbite (moderate)
- Overbite: Anterior openbite (mild)
- Upper incisor inclination: Labioversion (mild)
- Lower incisor inclination: Normal
- Interincisal angle: Normal
- Upper incisal display: Normal

- **Soft-tissue**

- Upper lip: Retrusion (moderate)
- Lower lip: protrusion

Maxillary advancement surgery (Le Fort I osteotomy) was performed, and mandibular setback (bilateral split sagittal osteotomy) with rigid internal fixation (RIF) followed by the placement of inter-maxillary elastics intraoperative.

2.2.2 Final assessment

- **Skeletal**

- Skeletal Class III (severe)
Maxilla: Normal
Mandible: Protrusion (moderate)
Chin point: Protrusion (severe)
- Normodivergent (mesocephalic) facial pattern

- **Dental**

- Class I molar relationship
- Overjet: normal

- Overbite: normal
- Upper incisor inclination: normal
- Lower incisor inclination: Normal
- Interincisal angle: Normal
- Upper incisal display: Normal

- **Soft-tissue**

- Upper lip: protrusion
- Lower lip: normal

The occlusion was checked manually, showing good molar contact. The patient's follow-up was marked with no need to release of maxilla-mandibular fixation due to post-operative airway embarrassment; no loss of teeth or alveolar bone; neither infra-orbital nor mental nerve function was altered.

3. DISCUSSION

This article gives an overview of the orthognathic surgery proposed and indicated for skeletal deformity. Dentofacial abnormalities can be correct by orthopedic therapy, orthognathic surgery, or combined treatments [5,6].

Orthognathic surgery is a surgical manipulation of the facial skeleton to achieve normal anatomy and functions [7].

The ideal time of treatment in a patient's development, when treatment is most effective, is a controversial issue. There is no absolute consensus on age limits for corrective therapy of facial deformity. Surgeons who recommend orthognathic surgery for children with facial deformities may be concerned about the negative effect of surgery on the future growth of the facial skeleton [8].

Orthognathic surgical correction of dentofacial deformities has a physical and psychological impact on quality of life (QoL) [9,10]. Also stable occlusion prevents the occurrence of temporomandibular joint disorders (TMJ) [3].

In skeletal class III cases, the lower incisors are usually retroclined while the maxillary incisors are commonly flared out. In our case, the presurgical orthodontics aimed to change the positions of the incisors in the proper angulation to allow the maximum set-back of the mandible. In some cases, the tooth extraction is required for retraction of the upper anterior teeth and decreases the crowding.

Bilateral sagittal split osteotomy of the mandible and Lefort osteotomy are surgical procedures to correct skeletal deformities. In this procedure, the osteotomy divides the bone's body so that the fragments can be moved forward or backward [11].

The duration of treatment was quite short in our patient, less than six months. The patient was young and healthy with no other associated diseases. The satisfactory result can be explained by the restoration of the relationship between the jaws and the soft tissues of the face.

Thus the labial force applied to the lower teeth has been reduced even though it is quite low; its persistence is considered to be an effective force to move the lower anterior teeth.

In our case, this is a skeletal deformity with major functional discomfort, hence the justified indication of orthognathic surgery. Concerning evolution and prognosis, the follow-up procedure was simple and satisfying. An orthodontic finishing was started in the 2nd week. At 1 month postoperative, there is a skeletal and functional improvement in the patient.

Table 1. Cephalometric analysis

Mesurements	Intial assesment	Severity
SNA	78.95	
SNB	82.55	
ANB	-3.60	***
FMA	22.63	*
APDI	101.51	***
ODI	61.66	*
A to N-Perp(FH)	-0.42	
B to N-Perp(FH)	6.54	***
Pog to N-Perp(FH)	9.09	***
FH to AB	98.61	***
A-B to mandibular plane	58.76	***
Wits appraisal	-11.90	***
Overjet	-3.35	**
Overbite	-1.99	*
U1 to FH	123.26	*
L1 to LOP	77.23	**
Interincisal angle	125.77	
Cant of occlusal plane	6.23	
U1 to NA(mm)	8.20	*
U1 to NA(deg)	33.61	**
Upper lip to E-plane	-5.93	**
Lower lip to E-plane	1.38	
Nasolabial angle	71.21	***

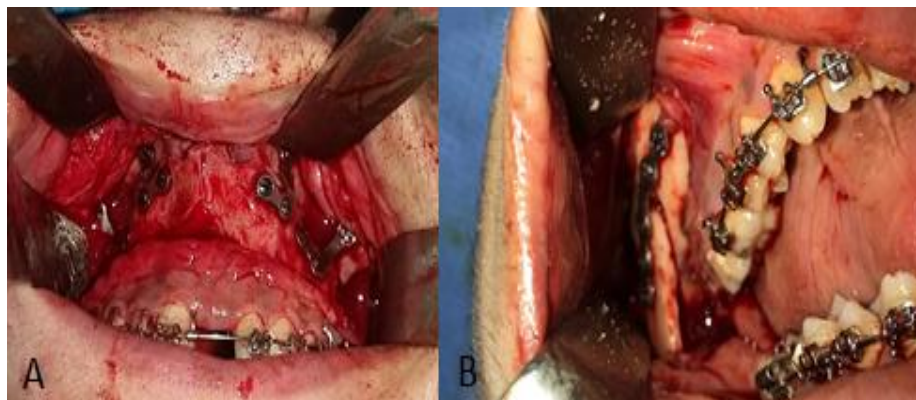


Fig. 3. Operating time: LeFort I osteotomy (A) bilateral sagittal osteotomy of the mandible (B)

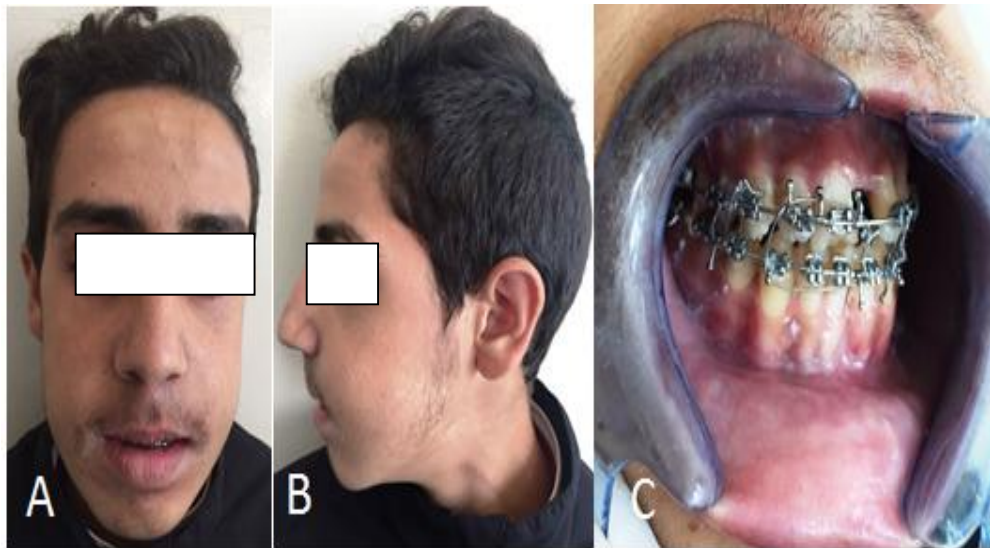

Fig. 4. Results of the surgical treatment: front view (A), profile view (B), intraoral view (C)
Duration of surgery: 120 min; estimation of blood loss: 150 ml; duration of hospital stay: 4 days

4. CONCLUSION

Restoring facial harmony generally improves self-esteem and social integration. Orthognathic surgery is able to correct the skeletal base of the face. A prior knowledge of clinical symptoms, as well as an appropriate selection of patients, can make a correct indication for surgery. Combined surgical and orthodontic management of Class III skeletal cases are the treatment of choice; the collaboration between the orthodontist and the maxillofacial surgeon is crucial.

CONSENT AND ETHICAL APPROVAL

As per university standard guideline, participant consent and ethical approval have been collected and preserved by the authors.

COMPETING INTERESTS

Authors have declared that no competing interests exist.

REFERENCES

1. Ngan P, Moon W. Evolution of Class III treatment in orthodontics. *Am J Orthod Dentofac Orthop.* 2015. DOI: 10.1016/j.ajodo.2015.04.012.
2. Zere E, Chaudhari PK, Sharan J, Dhingra K, Tiwari N. Developing Class III malocclusions: Challenges and solutions.

Clinical, Cosmetic and Investigational Dentistry; 2018.

DOI: 10.2147/CCIDE.S134303.

3. Itoh S, Nagata H, Murakami S, Ogura T, Nakagawa K, Takada K. Surgical orthodontic treatment of skeletal Class III malocclusion with anterior disc displacement without reduction (ADNR): A case report. *Clin Orthod Res;* 1999. DOI: 10.1111/ocr.1999.2.4.209.
4. KKL, WC F, EL. Malocclusion prevalence in an ethnic Chinese population. *Aust Dent J;* 1993.
5. Politis C, Daems L, De Temmerman G, Legrand P, Willems G. Orthognathic surgery. *Tijdschr Geneesk;* 2016. DOI:10.2143/TVG.72.05.2002074.
6. McIntyre GT. Treatment planning in Class III malocclusion. *Dent Update;* 2004. doi:10.12968/denu.2004.31.1.13.
7. Patel PK, Novia MV. The surgical tools: The le fort i, bilateral sagittal split osteotomy of the mandible, and the osseous genioplasty. *Clinics in Plastic Surgery;* 2007. DOI:10.1016/j.cps.2007.05.012.
8. Weaver N, Glover K, Major P, Varnhagen C, Grace M. Age limitation on provision of orthopedic therapy and orthognathic surgery. *Am J Orthod Dentofacial Orthop.* 1998;113(2):156–164.

9. Asada K, Motoyoshi M, Tamura T, Nakajima A, Mayahara K, Shimizu N. Satisfaction with orthognathic surgery of skeletal Class III patients. *Am J Orthod Dentofac Orthop*; 2015. DOI:10.1016/j.ajodo.2015.05.021.
10. Silva I, Cardemil C, Kashani H, Bazargani F, Tarnow P, Rasmusson L, et al. Quality of life in patients undergoing orthognathic surgery – A two-centered Swedish study. *J Cranio-Maxillofacial Surg*; 2016. DOI:10.1016/j.jcms.2016.04.005.
11. Gawande P, Halli R, Rudagi BM, Kini Y, Rajanikanth. Bilateral sagittal split osteotomy - A case report. *Pravara Med Rev*; 2013.

© 2020 Kerdoud and Slimani; This is an Open Access article distributed under the terms of the Creative Commons Attribution License (<http://creativecommons.org/licenses/by/4.0>), which permits unrestricted use, distribution, and reproduction in any medium, provided the original work is properly cited.

Peer-review history:
The peer review history for this paper can be accessed here:
<http://www.sdiarticle4.com/review-history/63700>