



Surgical Treatment of Chicken Bone Aspiration in the Chronic Period

Bayrakçi Onur¹ and Özdemir Derya^{1*}

¹*Thoracic Surgery Department, Ersin Arslan Education and Research Hospital, Gaziantep, Turkey.*

Authors' contributions

This work was carried out in collaboration between both authors. Author BO designed the study and wrote the first draft of the manuscript. Author ÖD managed the literature searches. Both authors read and approved the final manuscript.

Article Information

Editor(s):

(1) Dr. Wagih Mommtaz Ghannam, Mansoura University, Egypt.

Reviewers:

(1) Reza Ershadi, Tehran University Of Medical Science, Valiasr Hospital Tehran, Iran.
(2) Marília Loureiro, Centro Hospitalar do Porto, Centro Materno-Infantil do Norte, Portugal.

(3) Guillermo Yanowsky Reyes, University of Guadalajara, Mexico.

Complete Peer review History: <http://www.sdiarticle4.com/review-history/64577>

Case Study

Received 10 November 2020

Accepted 17 January 2021

Published 27 January 2021

ABSTRACT

Although foreign body aspiration is rare in adults, it is seen in all age groups. It is life threatening and causes death, especially in children. It is mostly removed by bronchoscopic interventions in early cases. It causes complications like recurrent pneumonia, pneumothorax, empyema, abscess, and bronchiectasis in patients with delayed diagnosis. Our case is a 58-year-old male patient who presented with a complaint of a cough that did not pass for months, with delayed diagnosis of foreign body aspiration (chicken bone). The foreign body could be unseen due to granulation tissue with rigid and flexible bronchoscope in the patient who applied with pneumothorax complication. Foreign body that cannot be removed by non-surgical method, with lateral thoracotomy, a piece of bone deeply located in the apical of the right lung with a consolidated circumference of approximately 1 cm was removed by wedge resection. As a result, detailed anamnesis has a very important place in foreign body aspiration. While most of the foreign body aspiration detected in the early period can be removed by bronchoscopy, most of the patients diagnosed late require surgical treatment.

Keywords: Bronchoscopy; disease mimicking; surgical treatment.

**Corresponding author: E-mail: dronurbayrakci@gmail.com;*

1. INTRODUCTION

Foreign body aspiration is a rare but life-threatening event and 0.16-0.33% of adult bronchoscopic cases are foreign body aspiration [1]. While most airway aspiration events occur in children, 25% of cases occur in adults [2,3]. It is seen as obstruction or asphyxia in the proximal airways in cases detected early in adults. Depending on the diagnostic delay in the chronic period; Bronchiectasis, obstructive emphysema, recurrent pneumonia, bronchial stenosis, lung abscess, pleural effusion, empyema, broncho-pleural fistula, endobronchial polyps, and costal osteomyelitis may develop [4]. Right pneumothorax was detected in the patient who presented with the complaint of persistent cough. The patient was operated on for the foreign body that could be unremoved by bronchoscopy after the thorax tube. The chicken bone that the patient aspirated 8 months ago was removed from inside the lung at the right apical.

2. PRESENTATION OF CASE

58 years old male patients; the patient, who was admitted to the hospital with complaints of a cough that did not go away for about 8 months, was followed up with medical treatment for a while. Recently, he was admitted to the emergency department due to his cough

complaints and shortness of breath. On physical examination, respiratory sounds were significantly reduced on the right, and diffuse rhonchus was detected. A right pneumothorax was detected in the radiograph taken in the emergency room, and a calcified lesion was observed at the apical Figs. 1, 2. When the history was deepened, it was understood that there was no previous cough complaint and it started suddenly, and the cough complaint was concurrent with the eating chicken with bone about 8 months ago; first thoracic tube and bronchoscopy were performed to the patient. Widespread secretion was seen, more prominent from the right upper lobe entrance. Bronchial injury area and distal hard granulation tissue were seen in the right upper lobe apical segment bronchus part with flexible bronchoscope. However, since the granulation tissue could be unopened, the foreign body could be clearly unseen and removed. After exploring with a lateral thoracotomy incision, the deeply located right upper apical, approximately 1 cm in size, consolidated foreign body (bone) was removed by wedge resection with the surrounding lung tissue Fig. 3. The patient, who had no complications in the early postoperative follow-up, was discharged on the 3rd day Fig. 4. On the 10th day control, it was observed that her complaints completely disappeared.

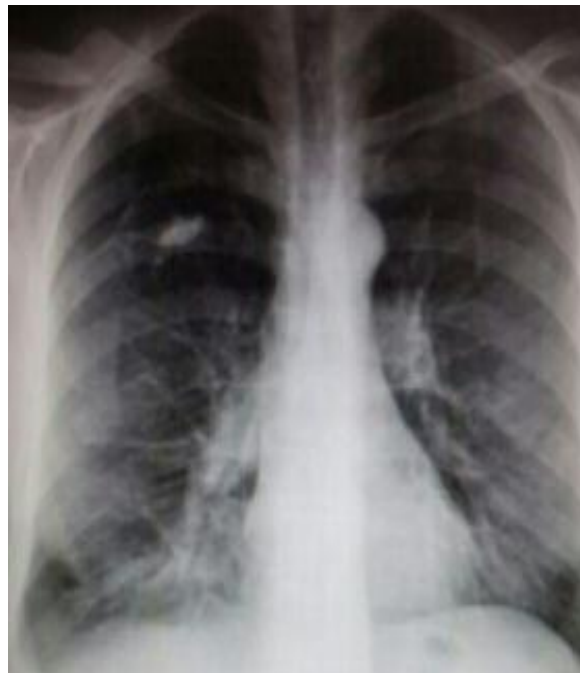


Fig. 1. Preoperative chest radiography

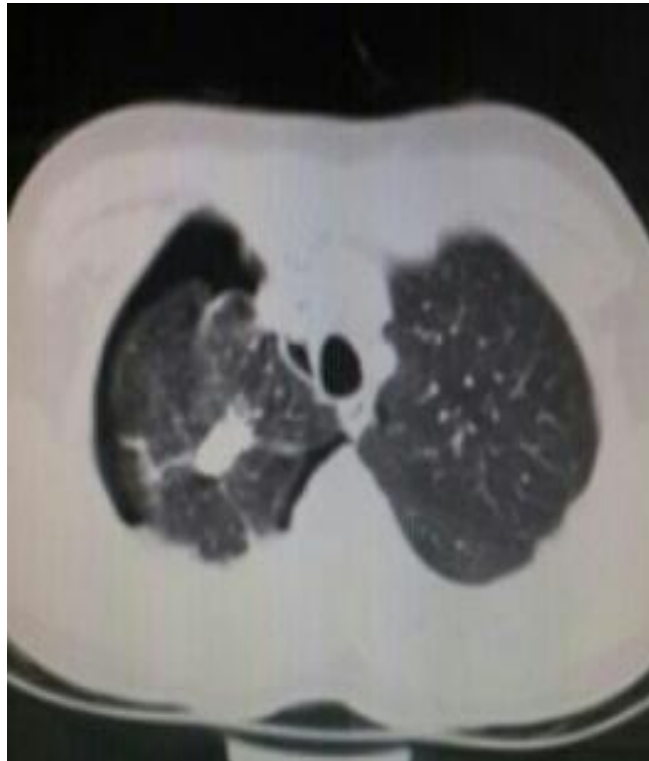

Fig. 2. Preoperative tomography image

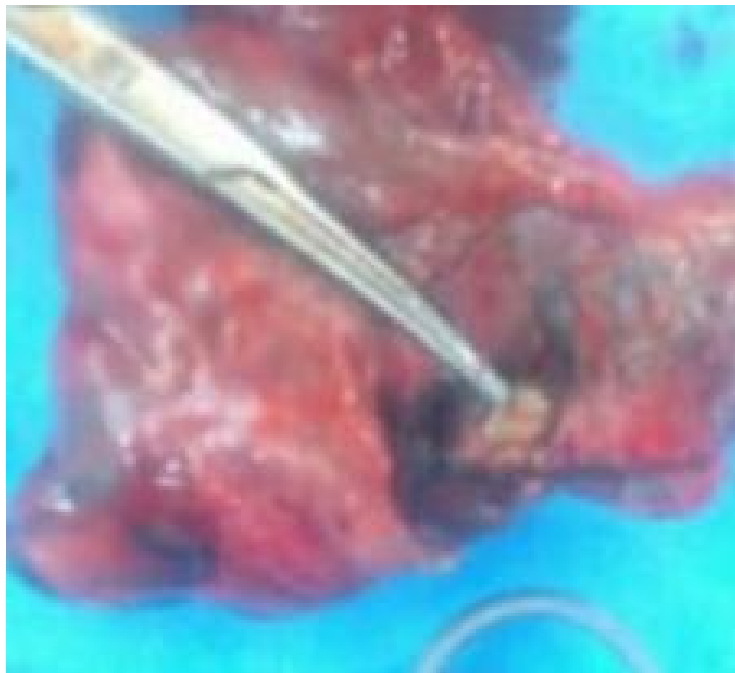


Fig. 3. Wedge resection (with chicken bone)

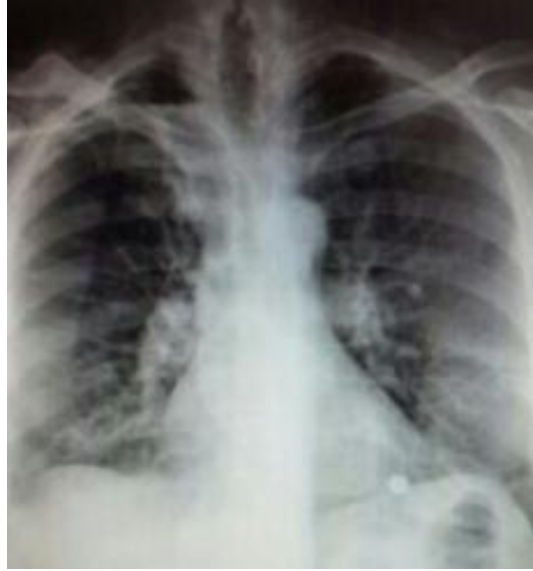

Fig. 4. Control chest radiography

3. DISCUSSION

80% of foreign body aspirations occur in children, and in adults it is often associated with impaired consciousness or swallowing [5,6]. In adults, it is usually manifested by cough, as well as hemoptysis, wheezing and shortness of breath (5,6) or the patient may remain asymptomatic. 80% of foreign bodies are not visible on a chest X-ray. CT findings include unilateral lung hyperlucency, bronchiectasis, atelectasis, lobar consolidation and / or pleural effusion [6]. In our case, opacitic appearance was present on both x-ray and CT because of bone. When foreign body aspiration is suspected, if not detected by physical examination and radiological examinations, the anamnesis should be deepened. The most recent treatment of choice for tracheobronchial foreign body aspirations is removal of the foreign body by rigid bronchoscope under general anesthesia [7]. If it cannot be removed by bronchoscopic methods, surgical approaches are required. Most of the foreign bodies detected in the early period are removed by bronchoscopic method. However, as time passes, the foreign body creates granulation tissue or causes complications. Due to the diagnostic delay, if any foreign body remains in the lung for a long time, it causes many complications like bronchiectasis, obstructive emphysema, recurrent pneumonia, bronchial stenosis, lung abscess [8]. Removal of aspirated foreign bodies should be done as soon as possible to prevent long-term complications.

4. CONCLUSION

Detailed anamnesis has a very important place in foreign body aspiration. Considering foreign body aspiration in patients is an indication for bronchoscopy, even if there is no clinical finding or history. It is possible to achieve early success in foreign body removal by bronchoscopy. However, surgical interventions are required in cases with delayed diagnosis that cannot be removed by bronchoscopy.

CONSENT AND ETHICAL APPROVAL

Informed consent form was obtained from the patient himself. The patient has permission to publish.

As per international standard or university standard written ethical approval has been collected and preserved by the author(s).

COMPETING INTERESTS

Authors have declared that no competing interests exist.

REFERENCES

1. Sehgal IS, Dhooria S, Ram B, et al. Foreign body inhalation in the adult population: Experience of 25,998 bronchoscopies and systematic review of

- the literature. *Respir Care*. 2015;60:1438-48.
DOI: 10.4187/respcare.03976
2. Baharloo F, Veyckemans F, Francis C, et al. Tracheobronchial foreign bodies: Presentation and management in children and adults. *Chest*. 1999;115:1357-62.
 3. Hsu Wc, Sheen Ts, Lin Cd, et al. Clinical experiences of removing foreign bodies in the airway and esophagus with a rigid endoscope: A series of 3217 cases from 1970 to 1996. *Otolaryngol Head Neck Surg*. 2000;122:450-4.
 4. Limper AH, Prakash UB. Tracheobronchial foreign bodies in adults. *Ann Intern Med*. 1990;112:604-609.
 5. Limper AH, Prakash UB. Tracheobronchial foreign bodies in adults. *Ann Intern Med*. 1990;112:604-9.
 6. Chen CH, Lai CL, Tsai TT, Lee YC, Perng RP. Foreign body aspiration into the lower airway in Chinese adults. *Chest*. 1997;112:129-33.
 7. Çelik P, Yorgancıoğlu A, Çelik O. Laringotrakeobronşial yabancı cisim aspirasyonu. *KBB Klinikleri*. 2000;2:50-56.
 8. Al-Majed SA, Ashour M, Al-Mobeireek AF, et al. Overlooked inhaled foreign bodies: Late sequelae and the likelihood of recovery. *Respir Med*. 1997;91:293-6.
DOI: 10.1016/S0954-6111(97)90033-0

© 2020 Onur and Derya; This is an Open Access article distributed under the terms of the Creative Commons Attribution License (<http://creativecommons.org/licenses/by/4.0>), which permits unrestricted use, distribution, and reproduction in any medium, provided the original work is properly cited.

Peer-review history:

The peer review history for this paper can be accessed here:
<http://www.sdiarticle4.com/review-history/64577>