



Salivary Megaliths: A Literature Review of Giant Salivary Sialoliths Larger than 30 mm

**Rosa Mostafavi Tabatabaee¹, Reza Mostafavi Tabatabaee^{2,3}
and Majid Sanatkhanian^{1*}**

¹Department of Oral and Maxillofacial Medicine, Faculty of Dentistry, Mashhad University of Medical Science, Mashhad, Iran.

²Rothman Institute of Orthopedics, Thomas Jefferson University, Philadelphia, Pennsylvania, USA.

³Joint Reconstruction Research Center (JRRC), Department of Orthopedic, Imam Hospital / University of Medical Sciences, Tehran, Iran.

Authors' contributions

This work was carried out in collaboration among all authors. All authors designed the study, performed the statistical analysis, wrote the protocol and wrote the first draft of the manuscript. All authors managed the analyses of the study. All authors managed the literature searches. All authors read and approved the final manuscript.

Article Information

DOI: 10.9734/JPRI/2019/v29i430245

Editor(s):

(1) Dr. Syed A. A. Rizvi, Department of Pharmaceutical Sciences, Nova Southeastern University, USA.

Reviewers:

(1) Janti Sudiono, Trisakti University, Indonesia.

(2) Antonione Santos Bezerra Pinto, IESVAP - Institute of Higher Education of Vale Do Parnaíba Ltd., Brazil.

Complete Peer review History: <http://www.sdiarticle3.com/review-history/50988>

Review Article

**Received 08 June 2019
Accepted 17 August 2019
Published 30 August 2019**

ABSTRACT

Background and Aim: Sialoliths are the most common salivary gland disease, Among them, there are rare sialoliths that have a size of more than 15 mm in one dimension, and salivary stones larger than 30 mm in one dimension is megalith that are very rare. Depending on the location and size of the stone, there are different diagnostic and therapeutic methods. In this article, we review the articles about salivary megaliths of unusual and gigantic size, the cause of stones formation and the method of diagnosis and treatment of salivary megaliths.

In this review article finding the number of reported salivary megaliths, causes, mechanism of stone formation, clinical presentation, diagnostic and therapeutic methods were written.

Materials and Methods: In this article review, Information was extracted through searches in databases by entering the keywords. Articles with incomplete data or articles that were less relevant to the topic or reported articles with giant stones smaller than 30 mm were excluded.

Results: A total of 77 articles, 85 patients suffering from megaliths and 86 salivary megaliths with a size of 30 mm and upwards have been reported up to now. The largest size is reported to be 83 mm. Megalith is more common in men and in the submandibular duct.

Conclusion: salivary megaliths are rare and Depend on the location of megaliths various diagnosis and treatment are available. The exact cause of the formation of them is unknown and further research is needed to identify the etiopathogenesis of the formation of these kind of gigantic salivary stones.

Keywords: Sialolith; giant sialolith; huge sialolith; remarkable sialolith; salivary megalith; submandibular gland; parotid gland; sublingual salivary duct; salivary gland.

ABBREVIATIONS

SM : *Submandibular Gland*

P : *Parotid Gland*

NR : *Not Reported*

1. BACKGROUND AND AIM

Salivary sialolith is one of the most common salivary diseases. The occurrence of sialoliths is estimated to be 0.15% in adult population with slightly more tendency in men [1-2]. About 90-80% of sialoliths occur in the submandibular salivary gland, 5-10% in the parotid gland and the rest in the sublingual glands and the secondary salivary glands [3-5] Saliva stasis and salivary viscosity play a more important role in salivary gland secretion than calcium content [1]. Salivary sialoliths are usually seen in the distal duct or in the hilum of the salivary glands [6] the typical size of salivary stones is between 1 and 10 Mm and their size rarely exceeds 15 mm. megaliths, are rare salivary giant stones of more than 30 mm in size [7].

The exact cause of the formation of salivary megalith is unknown so further research is needed to identify the etiopathogenesis of the formation of these huge salivary stones.

The purpose of this article is to review the reported articles of a kind of giant salivary sialoliths with a size of more than 30 mm (megaliths) in one dimension, the number of reported cases, and the study of the highest incidence of age and sex and the location of the salivary gland, diagnosis and treatment.

2. MATERIALS AND METHODS

2.1 Information Collection Method

In this article review, the information is obtained through the search for the key words "salivary stones, giant sialoliths, huge sialolith,

considerable size sialolith, salivary megalith, submandibular glands, parotid gland, sublingual salivary duct, salivary gland" in the databases: PubMed, ISI, Scopus, Medline, Embase, Google Scholar, SID, Chemical abstract, Black Well Synergy, Yahoo, science direct and Google search engine was extracted and no restrictions were placed on the publication date of the articles. The criteria for entry of articles into the study included the insertion of search words in the title section or the keywords of the articles, and there was no limitation on the publication date of the articles. Articles with incomplete data or articles that were less relevant to the subject or reported articles with salivary stones smaller than 30 mm were excluded from the study.

According to the definition in the articles, if the size of the sialoliths in any dimension is greater than 15 mm, is categorized as giant salivary stones and if larger than 30 mm in size is in megalith's group and they are rare. The decision to find and search for reported salivary megaliths larger than 30 mm was taken and the articles of giant sialoliths reported in the range of 15 to 30 mm were not included in this study, and ultimately 77 articles were obtained, in which a total 86 megaliths with a size of 30 mm and upper and also 85 patients suffered from these kind of salivary giant sialoliths were reported. (Table-1) Among these papers, the first salivary megalith reported in 1942 by Meyers in a 50-year-old male patient with a size of 50 mm in the submandibular duct was reported [8]. And three years later, in 1945, by Mustard and his colleagues, a 42-year-old patient, 56 mm in diameter, was reported to be a 6 mm larger than the first reported megalith [9]. The last salivary megaliths reported by Mostafavi Tabatabaee and Sanatkhani was in 2019 at a young male aged 30 years old with a size of 32 mm in the submandibular duct [10]. By reviewing the papers, we found that the most location of the occurrence of megaliths is in the submandibular

salivary gland and more in the duct it was seen and the patients were more men and more than 50 years old. Which 8 papers reported young patients aged 30 years or less, of which 6 were males and 2 were female. Two patients, with age 30, were male, one male was 28 years old, one was male with 27 years old, 2 were males with a 25-year-old, and 1 patient was a 22-year-old woman in submandibular parenchyma and a 35 mm salivary megalith in a 10-year-old submandibular duct. Largest megalith with size of 83 mm size was reported by Shahoon et al in 2015 in a man with the age of thirty years in the submandibular duct [11]. And the second largest case reported was in 2009 by Mr. Rai et al. In his 60-year-old mandibular duct of 72 mm [12]. The huge salivary megalith was in large measure by Cavina and Santoli in 1965 A size of 70 mm was reported in the submandibular duct (59 years old) [13]. Thus, it was observed that the largest salivary megalith in the submandibular duct with an age range of about 59 to 60 years old occurred, with the exception of the largest salivary megaliths that occurred in the patient's thirty-year-old, who again in 2019 were reported by Tabatabaee and Sanatkhani with a size of 32 mm in a male 30-year-old patient [10] the oldest patient was reported to have had a megalith, were Two patients, with the age of 75, one of them were reported by Udagatti, Chandra in submandibular parenchyma patients in 1997, with a size of 60 mm [14], and another in 2011 was reported by Cottrell et al in the submandibular duct [15]. The total number of female patients with megaliths was 7, the youngest of them was reported in 2004 by Raveenthiran, Rao in the submandibular duct of a 10-year-old girl with the size of 35 mm [16] and then in 2003 by Sutay and Contributors were reported in the submandibular parenchyma of a 22-year-old woman [17]. The highest age among patients suffer from megaliths were in women was reported by Leite et al. in 2011 in a 54-year-old female submandibular duct [18], and as a result, the youngest patient with salivary megalith in women was a girl with 10 years old. The oldest in men was patient with 75 years old [14-16]. The simultaneous bilateral megaliths in one patient, so far, were just one case in 2015 reported by Shahoon et al. In a 25-year-old submandibular duct with a size of 30 and 50 mm [11] the salivary megalith, which was simultaneously reported in the duct and parenchyma, was also 1 case. Cavina, Santoli reported it in 1965 in the duct and submandibular parenchyma in a 53-year-old patient with a maximum size of 60 mm [19]. Sublingual megalith was only one case, was

reported in 2010 by Gungormus et al In the 59-year-old patient parenchyma of sublingual gland [20]. The number of megaliths reported in parotid has been 3, of which 2 were in the duct and only one case was in the parenchyma [21-23]. The first megalith in Parotid duct in 1969 was reported by Rust and Messerly in the patient's parotid duct of a 66-year-old male patient measuring 51 mm [21] and then in 1992, by Iqbal and his colleagues reported with a size of 30 mm in a 48-year-old's parotid duct [22]. And the only megalith in parenchyma of parotid gland was reported by Kesse et al With a size of 50 mm in a 64-year-old male in 1998 [23].

2.2 Definition of Salivary Megalith and the History of It

Giant sialolith, or huge or megalith, according to the papers, refers to a sialolith which size is larger than 15 mm in one dimension. Mr. Meyer reported the first 50-mm salivary megalith in the 1942's in submandibular duct of a patient [8]. The largest megalith ever reported by Mr. Shahoon et al in 2015 was 83 mm in the submandibular duct [11]. Rai et al. reported a huge megalith with a size of 72 mm in the submandibular duct of the 60-year-old in 2009 [12]. Cavina et al. reported the third submandibular huge megalith with a size greater than 70 mm in 1965 in the submandibular duct of the 65-year-old patient [13]. As a whole, there are 86 salivary megaliths larger than 30 mm in diameter, has been reported which most of them were in the submandibular duct (Table 1).

Demographic variables: Salivary megaliths larger than 30 mm are rare stones that are slightly more likely to occur in men, ranging from 15 mm to 83-mm. Formation of salivary megaliths can occur at any age, but often occur in the third to sixth decades of life. The submandibular duct is seen as a common occurrence of sialoliths.

Etiology and pathogenesis: According to Harrison et al.'s theory the formation of the stone's nucleus in the submandibular glands is secondary due to sialadenitis and depends on the duration of the symptoms of sialadenitis [24]. According to their theory, during chronic sialadenitis of submandibular gland, inflammatory swelling may lead to a relative obstruction of the long duct with the stasis of the secreted material which is high in calcium. This causes the formation of a calcified core and then grows up and eventually becomes sialoliths.

Salivary sialoliths and megaliths can cause chronic obstructive sialadenitis (Fig.1-A) there are various sialadenitis (Fig.1-B), differentiation of sialadenitis from neoplasm is very important (algorithm in Fig. 2-A) also we should consider infections, neoplasm, obstruction of salivary duct or gland are in list of DDX (Fig. 2-B, Fig. 3-A).

We should always pay attention to saliva, discharge or not? (Fig. 3-B) To differentiation what is mentioned, we can use the mass limit, whether or not the mass is diffuse at all (Fig. 4).

What causes the occurrence of salivary stones and its gigantic type in the submandibular gland?

It seems that there are several factors in the incidence of more sialoliths in the sub mandibular gland compared to parotid gland, including:

1. Submandibular duct with a wider and longer diameter and more torsion than the Stenson duct.
2. The saliva flow in the submandibular gland is unlike the gravity of the earth.
3. Saliva of submandibular gland is an alkaline compared to saliva of parotid gland
4. The saliva of submandibular gland contains a large amount of mucin proteins, while the parotid gland's saliva is completely serous.
5. The calcium and phosphate content of the submandibular saliva is higher than other glands.

How does the formation of salivary stones begin?

Generally seems, the formation of salivary glands begins with oral retention in the salivary duct. The latest studies have done by Sialoendoscopy show the highest probability of saliva's retention in the submandibular duct. The mucosa of duct seen by the endoscope is white and without having vessels, and the salivary duct itself can lead to imperfect obstruction.

During the Sialoendoscopy, some specific features in the lumen and the salivary duct's wall were seen and reported by Yu et al. [5] a specific structure is a sphincter mechanism or muscular structure [25, 26]. This function is like a valve and can prevent the entrance of the foreign body to the inlet of the duct that runs along the anterior

part of the submandibular duct that can be related to the sialoliths in the submandibular salivary gland.

Marshall et al. [6,27,28] reported the results of a study of 120 submandibular glands and the presence of a valve in the first 3 mm of the Wharton duct. Another specific structure is the structure of the pond in the submandibular gland, which extends to the hilus-like area of the Sialoendoscopy, which is called a coma. This area may slow down the burning flow and cause the mineral deposits to become gradual stone formation such as the mucus plug or external foreign body.

Diagnosis: By correct history and proper examination, we find the presence of a salivary megalith. Since 80-90% of salivary sialoliths are due to the content of calcium and magnesium carbonate and phosphate, they are radiopaque so X-rays can easily detect them. Diagnostic procedures include radiography with plain film, sialography, ultrasonography, CT scan and CBCT, MRI sialography and Sialoendoscopy (Fig. 4): Diagnosis of Salivary Gland sialoliths [29].

Prohibition of Sialography: Use in conjunction with a contrast agent in the presence of salivary gland inflammation is prohibited.

Radiography with a plain film: The advantage is easy to use and inexpensive, but it susceptible to anatomical overlap, and radiolucent sialoliths are not visible.

Ultrasonography: The advantage use of US is the radiolucent sialoliths can be seen with it. But In cases of multiple salivary stones and small sialoliths below 2 cm, it doesn't produce acoustic shades, and thus doesn't provide an accurate diagnosis of the number of sialoliths.

CT: When we doubt the salivary gland stones, we use CT without contrast agent.

CBCT: Images from the CBCT of the duct's system are superior to the typical sialographic projection.

MRI Sialography: It has more Advantages than usual sialographic projection. The following three are used: 1. Allergy to iodine 2. Allergy to contrast agent 3. Patient With acute infection.

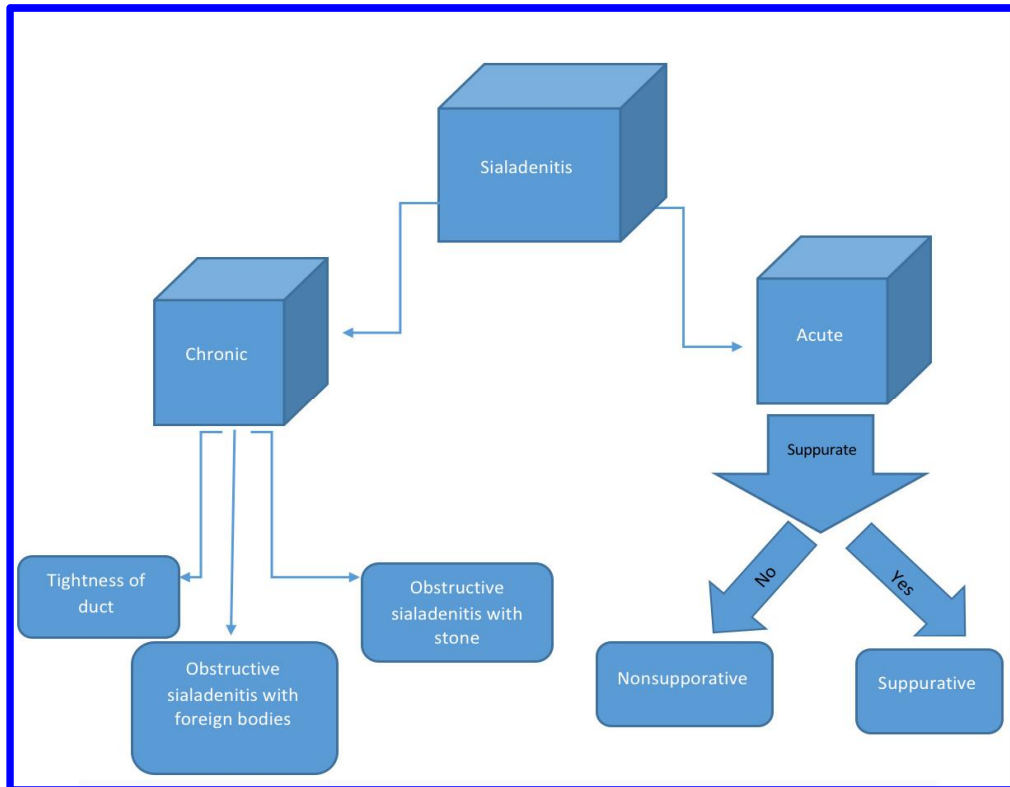


Fig. 1-A. An algorithm of various sialadenitis

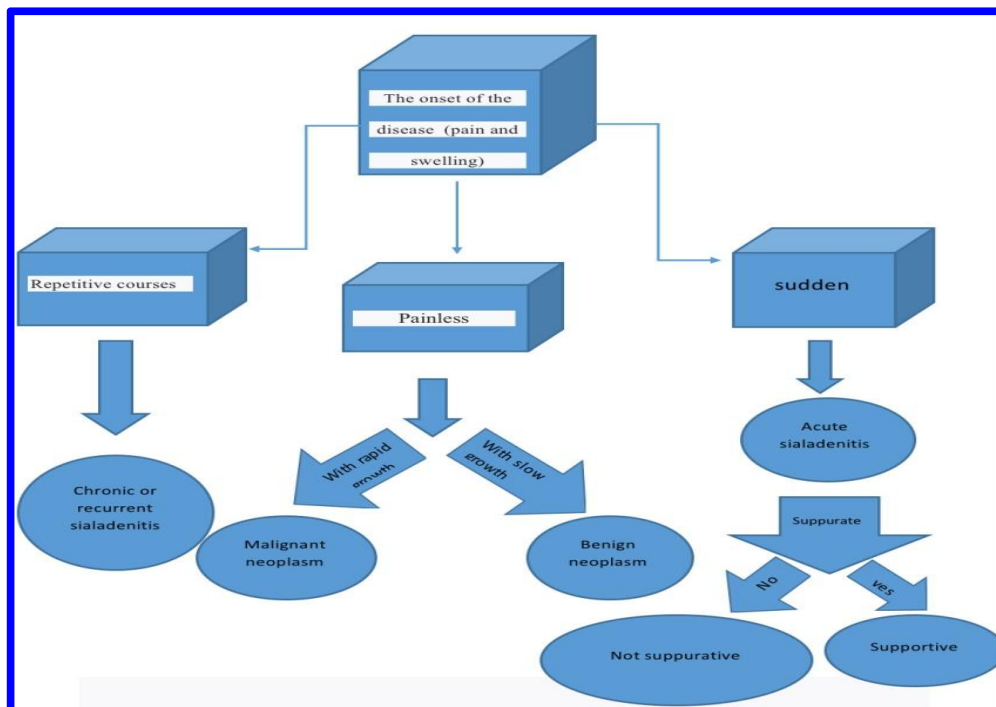


Fig. 1-B. Differential diagnostic algorithm of salivary gland stones and acute and chronic sialadenitis, and its variants

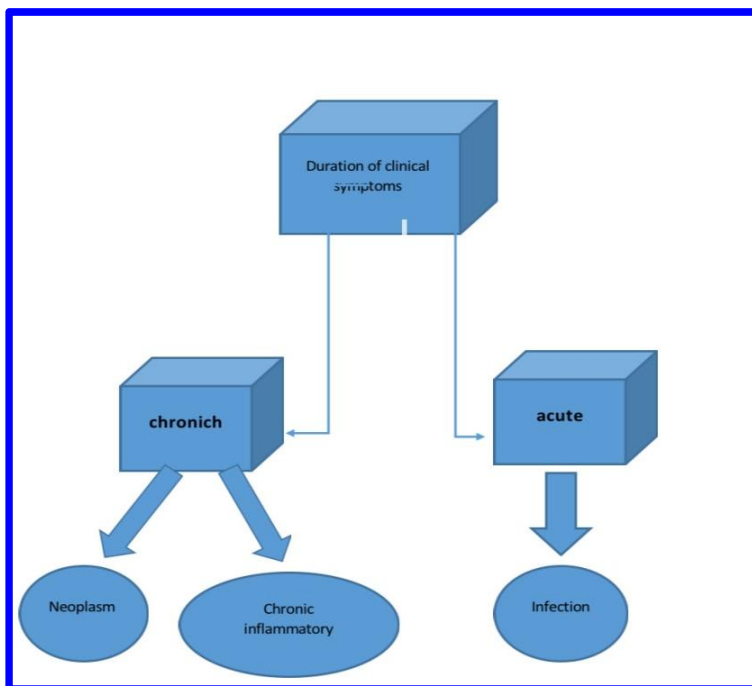


Fig. 2-a. Differential diagnostic algorithm of infection, chronic inflammation, and neoplasm, on the duration of clinical symptoms

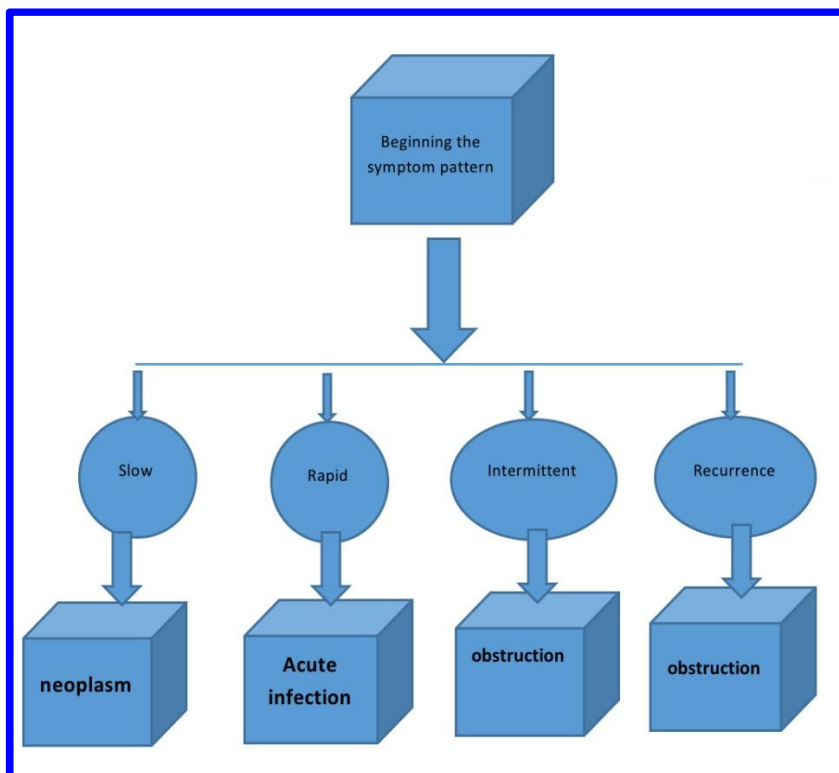


Fig. 2-B. Differential diagnostic algorithm for salivary duct obstruction, infection, and neoplasm, from the onset of the symptom pattern

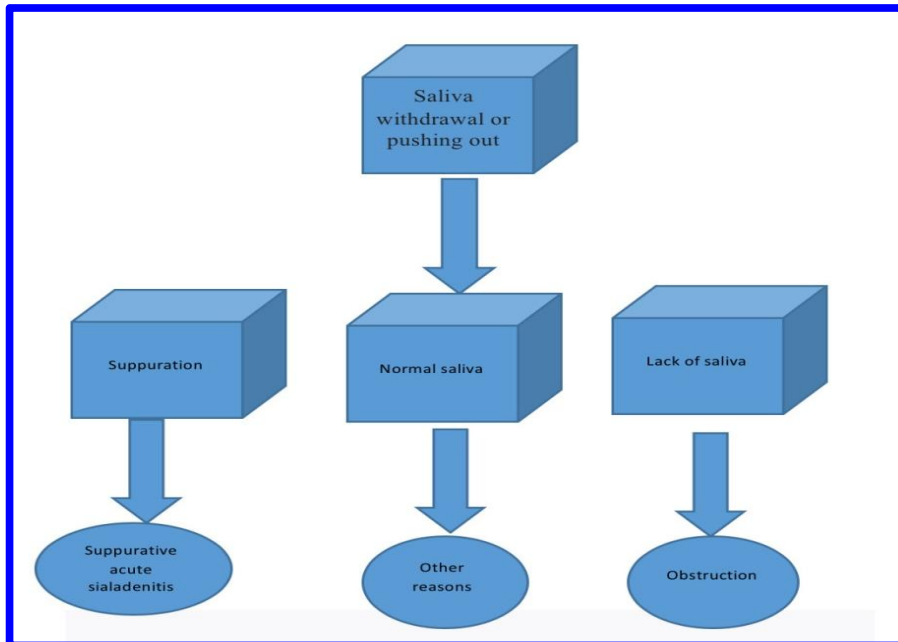


Fig. 3-A. Differential diagnostic algorithm for discharge of salivary dissipative function, from the saliva or pus

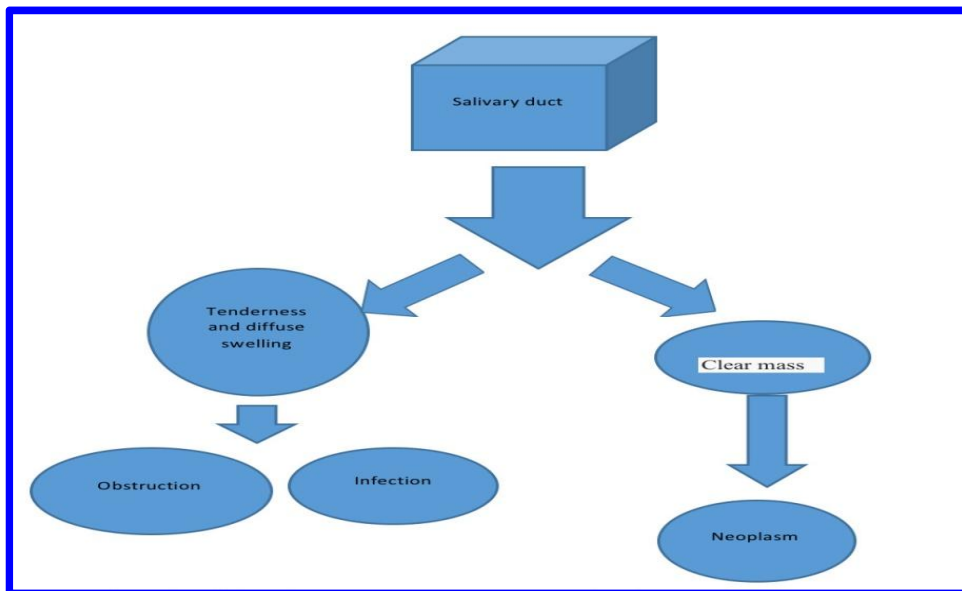


Fig. 3-B. Differential Diagnostic Algorithm of infection, obstruction, neoplasm with diffusion or cleared border mass

Prohibited MRI Sialography: 1. Patients with pacemakers 2. Those who are afraid of closed space. (Claustrophobia).

Sialoendoscopy

1. Diagnostic and therapeutic method

2. Provides access of deep ducts and intubates.
3. Possibility of evaluation of anatomy inside and outside the ducts using a small camera and the possibility of observation of stenosis and accessory canals in the duct.

An illustration of the anatomy of the salivary duct by sialography shows the presence of stones if any degree of glandular degeneration is associated with chronic disease. However, sialography increases the risk of cancer and the chance of perforation and displacement of retrograde stones by injection [17].

Ultrasonography is a non-invasive method for detecting stones. Sialoliths > 15 mm, especially with high minerals, are easily identified. Ultrasonography may detect radiolucent sialoliths [30]. The CT scans give us the exact location of each salivary stone of any size. But, it's an expensive tool [31]. Sialoendoscopy is a diagnostic and therapeutic method, even when X-rays and ultrasound are not able to detect sialoliths [32].

Radiographic View: Salivary stones in terms of radiography can have a radiopaque structure that may be homogeneous, or with a multi-layered structure. Some may also have a radiolucent view [9].

Sialoliths can cause chronic obstructive sialadenitis: Various sialadenitis has been shown in (Fig. 5).

Treatment: (Refer to Fig. 6).

Depending on the size of the salivary stone, treatment is different. If the stones are small, treatment is conservative, which includes water supply, sialagogue, administration and massage can be helpful and, if necessary, antibiotics are used [33]. Salivary megaliths are treated depending on where they are treated surgically or using Sialoendoscopy. Submandibular salivary sialoliths can be surgically removed through intraoral or Extraoral access. For megaliths that are completely in the duct and close to the orifice of duct, surgery with oral access is sufficient. It is cut along the Wharton duct, which must be noted that the nerve is not damaged because the Wharton duct is close to it. After the megalith is removed, try to open the duct, which is referred to as sialodochotomy and when it is sutured with the adjacent oral mucosa, it is referred to as sialodochoplasty.

Extra-oral methods are used for intra-gonadal sialoliths and those in the glandular umbilical cavity. Note that extra-oral access has a risk of injury to the mandibular marginal nerve [34,35].

Salivary megaliths may be split into smaller pieces using an additional shockwave lithotripsy or an endoscopic intracorporeal lithotripsy wave. The latter technique has recently been developed [33]. The additional shock wave lithotripsy divides megaliths into pieces of an average size of 0.7 mm in diameter. The best results in salivary lithotripsy are when the size of the divided stone is less than 1.2 mm [36]. Sialoendoscopy is performed under local anesthesia. The proper size of the Sialoendoscopy is determined after dilatation of salivary papilla.

Small salivary stones can be retrieved with a wire basket. Megaliths are divided by fiber optic laser lithotripsy. Intervention can be done with direct attention to this approach. It should be taken into account that Sialoendoscopy leads to duct perforation, which, of course, can be minimized with proper training [32,37].

Surgery to remove salivary megaliths from the submandibular duct [30,32]

Intraoral method: The purpose of this procedure is to dissect the Wharton duct and isolate it and subsequently remove the megalith. Instead of blind looking, and for avoiding movement the megalith in the floor of the mouth and duct, the anterior posterior part of sialolith on soft tissue is limited, so it couldn't move and it will be stable. This is done, by placing two deep sutures in the anterior and the other at the posterior of sialolith. An option for making radiopaque sutures with ionizing oil for observation in occlusal radiography is that stitches can be inserted correctly.

There are anatomical features that can be used to restrict the salivary duct. Sublingual plica is a prominent peak in the mucous membrane of the sublingual glandular contours of located on the oral floor along the lateral border of the tongue to the posterior of the lingual frenum. Very precisely it comes near pathway of anterior-posterior of duct and is located directly up, on the flat surface or slightly located on the side path of the Wharton duct. The second anatomical feature is the channel path, which gradually ascends the path from the gland to its apex toward the anterior. The depth of the suture can be calculated easily.

After the anterior suture is inserted, the posterior suture is carefully done to prevent slipping of the salivary sialoliths. Sutures should be long enough to be able to handle them manually, so

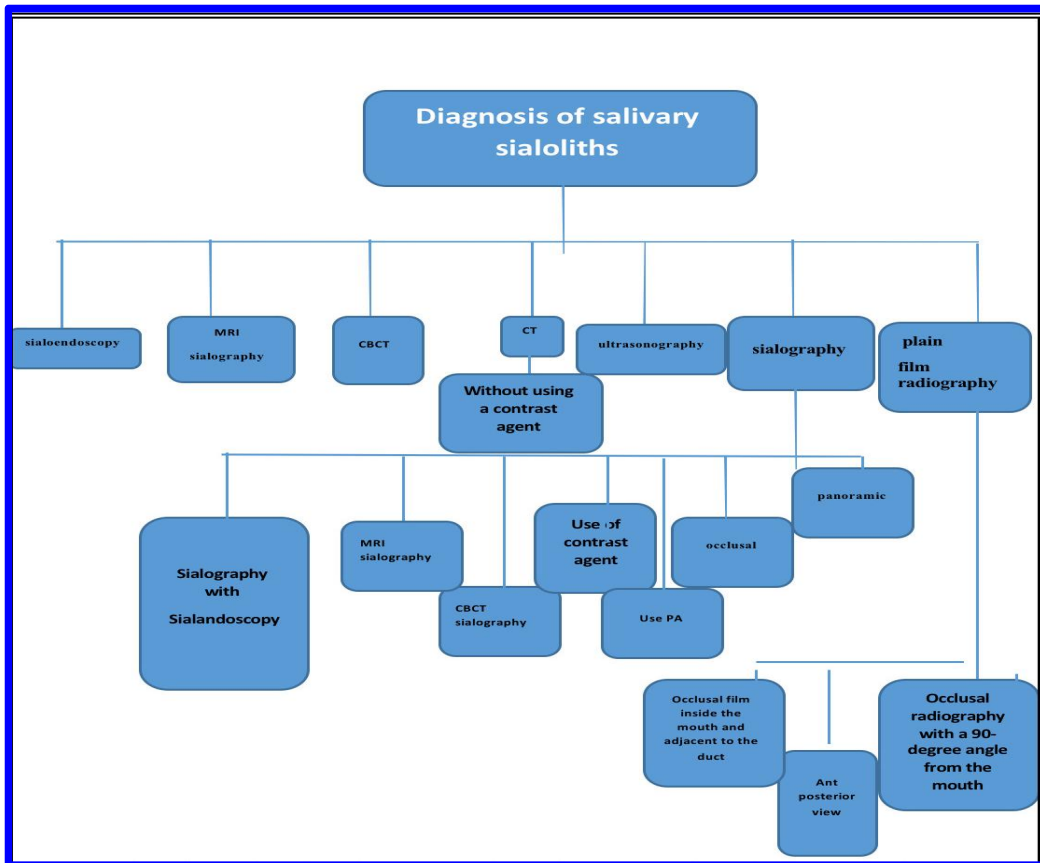


Fig. 4. Algorithm of various paraclinical diagnostic methods of salivary sialoliths

They will elevated the area of the surgery and tighten it and make it movable. Additional extra manual pressure below the oral cavity helps to determine the prominence of the area for surgery. Suture with extra-oral pressure facilitates a more accurate and simple diagnosis of the area.

The main rule in the removal of Wharton duct sialoliths that, if the stone is placed inside the duct, it will never be lost if it is initially identified and sufficiently isolated [38]. Direct crushing of sialoliths along the duct is not highly recommended, as it may cause ducts to destroyed, resulting in sialodochoplasty impossible and may cause leakage or stenosis [38-40].

Parts of salivary sialolith may also be lost to surrounding tissues and, as a result, cause infection. Conditions which reduction method is not only acceptable but also recommended:

1. If salivary sialolith is in the hole of the duct, in this case, the cutting on the sialolith will

help to destroy the stone, while at the same time allowing for a sialodochoplasty to allow by suturing exposed walls of the duct to the adjacent mucosa, it is done after inserting the lacrimal probe into the lumen of the duct;

2. When there is a megalith in the submandibular glands, pressing the gland upwards and anterior leads to a prominent protuberance of the sialolith within the mouth. Cutting through the mucosa leads to the protrusion of the stone out of the mouth. Cutting through the oral mucosa causes stone get out and, because the salivary gland is probably fibrotic and

Inactive and no further treatment is required. After identifying and isolating the Wharton duct and examining the significant anatomical structure, an initial cut in the narrow region of the sutured anteriorly. As the canal moves in the anterior direction, the moves of the salivary stones are placed in the upper anterior direction, so that one third of the anterior is relatively close to the surface of the oral mucosa.

The adjacent duct to the medial surface of the gland is under the tongue which upper bulge is touched by the plica of sublingual. The 2 cm incision is medial and parallel to the plica extending from the cuspid to the second premolar region.

If the incision is made to place the lateral position, the duct will pierce and damage the sublingual gland, causing increased iatrogenic risk and induction of oral ranula. Placing an infrared probe into the duct or isolating precisely immature tissues will be successful with curved mosquito hemostats. Dissection with mild deviations is medial or lateral. Backward sutures can be cut through the lateral mucosal tissues and tied to the adjacent teeth. For salivary stones that are located on the posterior, the mucous membrane extends backwards and the duct exposed until a prominence is observed. Follow the duct to the underside and detect and protect the nerve in the vicinity of Wharton. Putting a curved hemostat below it separates the stone. The longitudinal cutting through the superior wall of the duct that covers the salivary gland causes it to come out. The duct entrance is measured by insertion of an appropriate lacrimal probe after duct is washed by saline and the affected tuber is dipped to remove any remaining small stones or mucosal plugs.

Completion of this method can be done with an initial closure or sialodochoplasty if the initial

closure is done, the wall of the cut-off duct should not be sutured, as this will increase the risk of stricture. To reduce the amount of swelling in the oral floor from leakage of saliva and postoperative edema, close mucosal closure is a contraindication and surgical evacuation is essential. A serious risk to this method is to increase the precondition of saliva stasis, as well as the risk of recurrence, which can be avoided by dochoplasty. Opening the new duct made in each part in the horizontal section of the duct is recommended until the saliva removal is removed. The longitudinal cutting of the upper duct arises backward. The edges expand sideways, and each side is sutured with its adjacent oral mucosa with two subtle absorbent sutures. If possible, a single suture is inserted through the upper wall of the duct at the proximal end of the longitudinal incision to allow the mucus to be placed on it. Anterior duct closure is optional for dochoplasty to induce salivary flow through a new opening. Periodic duct opening and sialogogue guarantee the opening of a new duct.

Lithotripsy: An electrocorporeal lithotriptic shock wave is an old technique used as a non-invasive technique. In 1986, Marmary was the first to report sialoliths fragments using shock waves. At that time, large machines had a very large focus, but the development of smaller machines led to focused waves, which improved the performance of this technique.

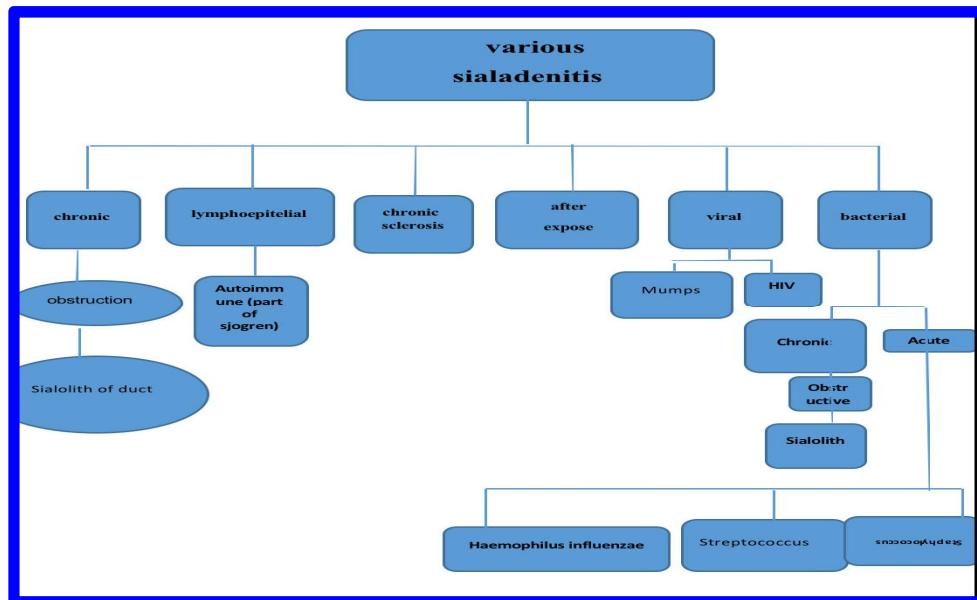


Fig. 5. Algorithm for various types of sialadenitis

Iro et al. Used a shockwave lithotripsy sialolith using a piezoelectric lithotripter to treat 35 stones and found that all sialoliths were divided and fragmented but only showed 40% of the removal of the barrier. A study was also carried out by Yoshizaki et al., Which only showed stone-to-sludge decomposition. Due to the need for advanced equipment and poor results, this technique seems not to be useful as continuous routine therapy. Instead of using interventional techniques and endoscopy or surgical intervention, it has been proven to be useful for the treatment of salivary sialoliths.

Items that are not approved by the US FDA for the treatment of sialoliths by extra-corporal SHOCK WAVE lithotripsy include:

1. Patients with narrow ducts in the distal portion of the duct.
2. Patients with synthetic pacemaker
3. Pregnant women
4. Acute salivary glandular inflammation
5. Other inflammatory processes of the head and neck.

Laser Sialolitomy: Azaz and colleagues reported a sialolitomy using Sharplan's CO₂ laser in 47 patients and concluded that the treatment with almost no bleeding results in at least minimal fear and discomfort during the recovery period. But there is no further benefit than the usual surgical treatment. As a blind method, this method does not seem to be a practical way to remove saliva stones, given that the tissue destruction rate is unknown and the need for specialist equipment with lack of specific benefits and it seems this method is not practical for removal of sialoliths.

Interventional Sialoendoscopy: Endoscopic system involves diagnosis and intervention of interventional Sialoendoscopy, papillary dilator, forceps, wire wrap (3-6 wires), and electro-hydraulic lithotripter. Local anesthesia is by lingual nerve block and 2% lignocaine perfusion through the hole. The endoscope is washed frequently with a 0.9% sodium chloride solution, which dilates the duct a little, clears the endoscope and eliminates pus, dandruff and occasional blood.

The device is inserted into the diaphragm or the anterior duct through the hole of the Wharton duct or with a small cut; the diameter of the papilla increases with the dilator. The first is a diagnostic procedure and can fully examine the duct system. An interventional endoscope is

required when the stone is in place. Wire or forceps can remove small round sialoliths can be removed by wire or forceps. The larger stones should be divided and split and then removed with a wire or forceps. When there is only obstruction, the balloon expansion can be done, and if there are mucin plugs, it can be removed through the forceps or cleared through the endoscope by continuous suction. Interventional and surgical Sialoendoscopy can jointly used to treat multiple sialoliths. The initial treatment results are satisfactory, but long-term results have not yet been evaluated.

Interventive Sialoendoscopy is useful in treating cases of multiple salivary stones, and in cases where the diameter of the sialoliths is about 4 to 5 mm; it is useful for those that are freely located in the duct.

Sialoliths larger than 4-5 mm in diameter are broken up first and for access to salivary stones from baskets, gongs or laser fibers; dilatation of the entrance of the duct is used to increase the size of the entry. To clean the derbies and treat the inflammation the duct, it is necessary to wash with saline or steroid droplet injection. After the sialoliths are removed, the endoscope will be used to ensure that all sialoliths are removed, and then a stent is placed to keep the duct out.

Submandibular gland removals: Removal of the gland is only performed when small sialoliths are located in the perpendicular portions of the duct from the coma to the hilus (umbilical cord) or within the gland, which are not accessible through oral surgery. And cause obstructive symptoms (24). With the availability of an interventional endoscope, this can even be avoided.

Side effects after removing the submandibular salivary gland: 1. Temporary or permanent mandibular marginal nerve damage. 2. Temporary or permanent sublingual nerve damage. 3. Temporary or permanent sublingual nerve paralysis.

Side effects after removing parotid gland (parotidectomy): 1. Temporary nerve damage 2. Permanent nerve damage 3. Loss of Great Auricular nerve 4. Frey syndrome.

Other complications of removal of salivary gland: Wound infection, salivary fistula, Hematoma, Sialosel, Hypertrophic scar, Inflammation from residual sialoliths.

Table 1. Salivary megaliths larger than 30 mm in size at least one dimension

Number	Study	Sex	Age	Gland	Location	Size
1	Meyers [8]	Male	50	SM	Duct	50
2	Mustard [11]	Male	42	SM	Duct	56
3	Guernsey [40]	Female	65	NR	Parenchyma	33
4	Allen [41]	Male	49	SM	Duct	35
5	Cavina/ Santoli [13]	Male	59	SM	Duct	70
6	Cavina/ Santoli [19]	Male	53	SM	Both	60
7	Hoggins [42]	Male	52	SM	Parenchyma	50
8	Rust/ Messerly [21]	Male	66	Parotid	Duct	51
9	Rust/ Messerly [21]	Male	58	SM	Parenchyma	35
10	Brusati [43]	Male	55	SM	Parenchyma	31
11	Raskin, et al. [44]	Male	52	SM	Duct	55
12	Zakaria [45]	Male	70	SM	Parenchyma	33
13	Koshal/ Naik [46]	Male	40	SM	Duct	50
14	Isacsson/ Persson [47]	Male	48	SM	Duct	36
15	Naraynsingh [48]	Male	28	SM	Parenchyma	60
16	Frame/ Smith [49]	Male	50	SM	Parenchyma	30
17	Kaltman/ Eichner [50]	Male	53	SM	Parenchyma	45
18	Lakhoo/ Mannell [51]	Male	37	SM	Duct	65
19	Tinsley [52]	Male	48	SM	Parenchyma	50
20	Bamgbelu [53]	Male	55	SM	Duct	35
21	Asfar, et al. [54]	Male	55	SM	Parenchyma	38
22	Hubar, et al. [55]	Male	65	SM	Duct	52
23	Martin, et al. [56]	Male	60	SM	Parenchyma	60
24	Akin/ Esmer [57]	Male	45	SM	Parenchyma	45
25	Iqbal, et al. [22]	Male	48	Parotid	Duct	30
26	Paul/ Chauhan [58]	Male	45	SM	Duct	45
27	Udagatti/ Chandra [14]	Male	75	SM	Parenchyma	60
28	Kesse, et al. [23]	Male	64	Parotid	Parenchyma	50
29	Eiraku, et al. [59]	Male	56	SM	Duct	51
30	Bodner [66]	Male	50	SM	Duct	50
31	Bodner [60]	Male	46	SM	Duct	32
32	Bodner [60]	Male	25	SM	Duct	32
33	Bodner [60]	Male	45	SM	Duct	30
34	Siddiqui [61]	Female	52	SM	Duct	30
35	Vital et al. [62]	Male	70	SM	Duct	60
36	Sutay et al. [17]	Female	22	SM	Parenchyma	37
37	Akimoto et al. [63]	Male	70	SM	Duct	45
38	Raveenthiran/ Rao [16]	female	10	SM	Duct	35
39	Yildirim [64]	Male	56	SM	Parenchyma	30
40	Chan/ Patel [65]	Male	27	SM	Duct	35
41	Ledesma-Montes, et al. [7]	Male	34	SM	Duct	36
42	Alkurt/ Peker [66]	Male	65	SM	Duct	31
43	Rai/ Burman [12]	Male	60	SM	Duct	72
44	Patil, et al. [67]	Male	50	SM	Duct	38
45	Emegoakor, et al. [35]	Male	65	SM	Duct	50
46	Krishnan, et al. [68]	Male	41	SM	Duct	34
47	Huang, et al. [69]	Male	57	SM	Duct	40
48	El Gehani, et al. [70]	Male	41	SM	Duct	35
49	El Gehani, et al. [70]	Male	48	SM	Parenchyma	30
50	Khen/ Abdeen [71]	Male	53	SM	Duct	33
51	Gungormus et al. [20]	Male	59	Sublingual	Parenchyma	32
52	Silva-Junior et al. [72]	Male	58	SM	Duct	35
53	Cottrell et al. [15]	Male	75	SM	Duct	30
54	Leite et al. [18]	Female	54	SM	Duct	35
55	Babu L/ Jain [73]	Male	50	SM	Duct	62
56	Iqbal, et al. [74]	Male	55	SM	Duct	35
57	Fowell/ MacBean [31]	Male	58	SM	Duct	41

58	Rauso, et al. [75]	Male	56	SM	Duct	56
59	Tyagi, et al. [76]	Male	69	SM	Duct	35
60	Pandarakalam, et al. [77]	male	68	SM	Duct	40
61	Goyal, et al. [34]	male	40	SM	Duct	50
62	Singh [78]	male	55	SM	Duct	37
63	Banerjee et al. [79]	Male	50	SM	Duct	35
64	Rodrigues [80]	Male	48	SM	Duct	45
65	Shahoon, et al. [11]	Male	25	SM (bilateral)	Duct	50&30
66	Shahoon, et al. [11]	Male	30	SM	Duct	83
67	Arslan, et al. [81]	Male	42	SM	Parenchyma	35
68	Sari/ Sahin [82]	Male	55	SM	Duct	40
69	Demircan [83]	Male	62	SM	Duct	30
70	Bhullar [84]	Male	45	SM	Duct	31
71	Akinyamoju/ Adisa [85]	Male	54	SM	Duct	44
72	Omezli et al. [86]	Male	35	SM	Duct	37
73	Gill d, et al. [87]	Male	48	SM	Duct	57
74	Omezli et al. [86]	Male	59	SM	Duct	38
75	Abdullah O [88]	Male	37	SM	Duct	36
76	Oliveira T, et al. [89]	Male	42	SM	Duct	30
77	Goh L, et al. [90]	Male	34	SM	Duct	40
78	Seddika A, Ferdousi Am, et al. [91]	NR	NR	SM	Duct	41
79	Weinberg A, Albers AE [92]	NR	59	SM	Parenchyma	38
80	Lim EH ,et al. [93]	Male	59	SM	Parenchyma	50
81	Iwai T, et al. [94]	Male	53	SM	Parenchyma	41
82	Sakthivel P ,et al. [95]	Male	42	SM	Duct	50
83	Rodrigues G, et al. [96]	Female	48	SM	Duct	45
84	Mathew AI [97]	Female	52	SM	Parenchyma	40
85	Tabatabaee R, Sanatkhani M [10]	Male	30	SM	Duct	33

Abbreviations: SM: submandibular gland, P: parotid gland, NR: not reported

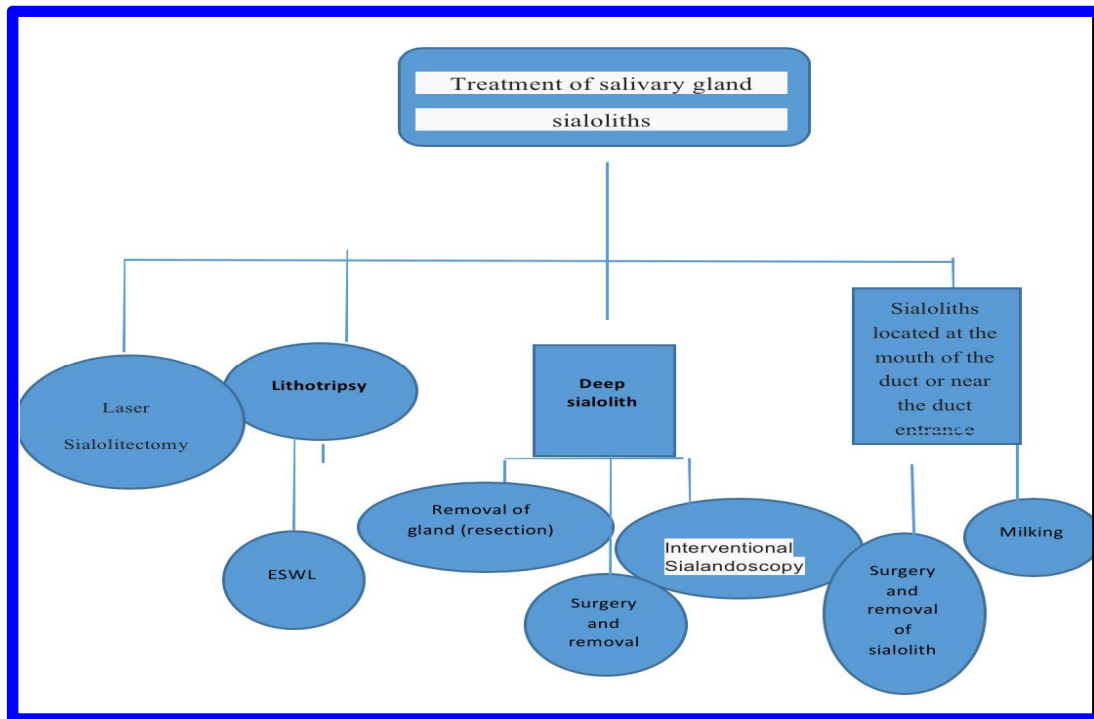


Fig. 6. Algorithm for treatment of salivary gland sialoliths

3. RESULTS

A total of 77 articles, 85 patients suffering from megalith and 86 salivary megaliths with a size of 30 mm upwards have been reported up to now. The largest size is reported to be 83 mm. Megalith is more common in men and in the submandibular duct. Salivary megaliths larger than 30 mm in size are very rare, and in case of dealing with these megaliths, a case report is required by the therapist. More research is needed to recognize the etiopathogenesis of megaliths. There are different treatment options depending on the size and location of the sialoliths. The submandibular gland should be removed in cases where salivary megaliths are inserted into the gland and are not accessible to oral surgery. However, with the availability of interventional endoscopes, even this can be prevented. Sialoendoscopy of the new diagnostic and therapeutic technique for megaliths, however, some salivary megaliths have been surgically removed without the need for Sialoendoscopy and the recurrence have not been reported.

4. CONCLUSION

Salivary megaliths are rare and Depend on the location of megaliths various diagnosis and treatment are available. The exact cause of the formation of them is unknown and further research is needed to identify the etiopathogenesis of the formation of these kind of gigantic salivary stones.

CONSENT

It is not applicable.

ETHICAL APPROVAL

It is not applicable.

COMPETING INTERESTS

Authors have declared that no competing interests exist.

REFERENCES

1. Iro H, Zenk J, Escudier MP, Nahlieli O, Capaccio P, Katz P, et al. Outcome of minimally invasive management of salivary calculi in 4,691 patients. *Laryngoscope*. 2009;119(2):263-8.
2. Seifert G. *Diseases of Salivary Glands*. Berlin, Germany: Springer; 2000.
3. Escudier MP, Brown JE, Drage NA, McGurk M. Extracorporeal shockwave lithotripsy in the management of salivary calculi. *Br J Surg*. 2003;90(4):482-5.
4. McGurk M, Escudier MP, Brown JE. Modern management of salivary calculi. *Br J Surg*. 2005;92(1):107-12.
5. Yu C, Yang C, Zheng L. Sialoendoscopic findings in patients with obstructive sialadenitis: Long-term experience. *British Journal of Oral and Maxillofacial Surgery*; 2013.
6. Capaccio P, Bottero A, Pompilio M, Ottaviani F. Conservative transoral removal of hilar submandibular salivary calculi. *Laryngoscope*. 2005;115(4):750-2.
7. Ledesma-Montes C, Garcés-Ortiz M, Salcido-García JF, Hernández-Flores F, Hernández-Guerrero JC. Giant sialolith: Case report and review of the literature. *Journal of Oral and Maxillofacial Surgery*. 2007;65(1):128-30.
8. Meyers H. Large calculus in submaxillary gland. *Dent Digest*. 1942;48:420.
9. Mustard T. Calculus of unusual size in Wharton's duct. *Br Dent J*. 1945;79(2):129.
10. Mostafavi Tabatabaee R, Sanatkhan M. Report of a giant sialolith of remarkable size in Submandibular duct. *J Mash Dent Sch*. 2019;43(2): 209-16.
11. Shahoon H, Farhadi S, Hamedi R. Giant sialoliths of Wharton duct: Report of two rare cases and review of literature. *Dent Res J (Isfahan)*. 2015;12(5):494-7.
12. Rai M, Burman R. Giant submandibular sialolith of remarkable size in the comma area of Wharton's duct: A case report. *J Oral Maxillofac Surg*. 2009;67(6):1329-32.
13. Cavina C, Santoli A. Su alcuni casi di calcolosi salivare di particolare interesse. *Minerva Stomatol*. 1965;14:90.
14. Udagatti V, Chandra S. Giant sialolith (megalith) of submandibular salivary gland. *The Journal of Laryngology and Otology*. 1997;109:767-9.
15. Cottrell D, Courtney M, Bhatia I, Gallagher G, Sundararajan D. Intraoral removal of a giant submandibular sialolith obstructing Wharton's duct: A case report. *Journal of the Massachusetts Dental Society*. 2011; 60(2):14-6.
16. Raveenthiran V, Rao PH. Giant calculus in the submandibular salivary duct: Report of the first prepubertal patient. *Pediatric Surgery International*. 2004;20(2):163-4.
17. Sutay S, Erdag TK, Ikiz AO, Guneri EA. Large submandibular gland calculus with

- perforation of the floor of the mouth. *Otolaryngology-Head and Neck Surgery*. 2003;128(4):587-8.
18. Leite T, Blei V, Oliveira D, Robaina F, Janini M, Meirelles V. Giant asymptomatic sialolithiasis. *International Journal of Oral-Medical Sciences*. 2011;10:175-8.
 19. Cavina C, Santoli A. Some cases of salivary calculi of particular interest. *Minerva stomatologica*. 1965;14:90.
 20. Güngörmüş M, Yavuz MS, Yolcu Ü. Giant sublingual sialolith leading to dysphagia. *Journal of Emergency Medicine*. 2010; 39(3):e129-e30.
 21. Rust TA, Messerly CD. Oddities of salivary calculi. *Oral Surgery, Oral Medicine, and Oral Pathology*. 1969;28(6):862-5.
 22. Iqbal SM, Murthy JG, Sharma N. Giant parotid calculus. An unusual presentation. *Journal of Laryngology and Otology*. 1992; 106(5):446-7.
 23. Kesse W, Shehab Z, Courteney-Harris R. A megalith of the parotid salivary gland. *The Journal of Laryngology & Otology*. 1998;112(8):784-5.
 24. Harrison JD, Epivatianos A, Bhatia SN. Role of microliths in the aetiology of chronic submandibular sialadenitis: a clinicopathological investigation of 154 cases. *Histopathology*. 1997;31(3):237-51.
 25. Manson DK. CDM. *Salivary glands in health and diseases*. London, UK: Saunders; 1975.
 26. Katz P. [Endoscopy of the salivary glands]. *Ann Radiol (Paris)*. 1991;34(1-2):110-3.
 27. Marchal F, Kurt AM, Dulguerov P, Lehmann W. Retrograde theory in sialolithiasis formation. *Arch Otolaryngol Head Neck Surg*. 2001;127(1):66-8.
 28. Marchal F, Becker M, Dulguerov P, Lehmann W. Interventional sialendoscopy. *Laryngoscope*. 2000;110(2 Pt 1):318-20.
 29. Lustmann J, Regev E, Melamed Y. Sialolithiasis. A survey on 245 patients and a review of the literature. *Int J Oral Maxillofac Surg*. 1990;19(3):135-8.
 30. Yoshimura YIY, Odagawa T. Sonographic examination of sialolithiasis. *J Oral Maxillofac Surg* 1989;47:907-12.
 31. Fowell C, MacBean A. Giant salivary calculi of the submandibular gland. *Journal of Surgical Case Reports*. 2012;2012(9):6.
 32. Nahlieli OBAM. Sialendoscopy: Three years' experience as a diagnostic and treatment modality. *J Oral Maxillofac Surg*. 1997;55:912-18.
 33. FWM. Sialolithiasis. *Otolaryngologic Clinics of North America*. 1999;32:819-34.
 34. Goyal L, Salim M, Saini S. Rare giant submandibular gland calculus: A case report. *Journal of Evolution of Medical and Dental Sciences*. 2013;2(45):8823-7.
 35. Emegoakor C, Chianakwana G, Ugonabo M, Madubogwu C, Iloabachie I, Akam A. An unusually large submandibular gland stone. A Case Report. *Nigerian Journal of Surgery*. 2009;15(1-2):15-7.
 36. Zenk JWG, Hosemann MD, Iro H. Diameters of the main excretory ducts of the adult human submandibular and parotid gland—A histological study. *Oral Surg Oral Med Oral Pathol Oral Radiol Endo*. 1998;85:576-80.
 37. FM. *Sialendoscopy. Salivary Gland Disorders*. Berlin Heidelberg New York: Springer. 2007;127-47.
 38. Baumash H, Mandel L. Surgical excision of miniature sialoliths in Wharton's duct. *Oral Surgery, Oral Medicine and Oral Pathology*. 1959;12(2):165-72.
 39. Yu CQ, Yang C, Zheng LY, Wu DM, Zhang J, Yun B. Selective management of obstructive submandibular sialadenitis. *Br J Oral Maxillofac Surg*. 2008;46(1):46-9.
 40. Guernsey LH. Giant sialolith; Report of a case. *Oral Surgery, Oral Medicine, and Oral Pathology*. 1953;6(10):1230-2.
 41. Allen N. A sialolith within the submaxillary duct and gland: Report of case. *Journal of Oral Surgery*. 1956;14(1):65-7.
 42. Hoggins G. Large calcified mass in the submaxillary gland. *Oral Surgery, Oral Medicine, Oral Pathology*. 1968;25(5):679-81.
 43. Brusati R, Fiamminghi L. Large calculus of the submandibular gland: Report of case. *Journal of Oral Surgery (American Dental Association: 1965)*. 1973;31(9):710-1.
 44. Raksin S, Gould S, Williams A. Submandibular duct sialolith of unusual size and shape. *Journal of oral surgery (American Dental Association: 1965)*. 1975;33(2):142-5.
 45. Zakaria M. Giant calculi of the submandibular salivary gland. *British Journal of Oral Surgery*. 1981;19(3):230-2.
 46. Koshal K, Naik R. Giant submaxillary sialolith. *Journal of the Indian Medical Association*. 1981;77(1):14.
 47. Isacson G, Persson NE. The gigantiform salivary calculus. *International Journal of Oral Surgery*. 1982;11(2):135-9.

48. Naraynsingh V. Giant submandibular gland calculi. *J Oral Maxillofac Surg.* 1985;43(5): 384-5.
49. Frame J, Smith A. Large calculi of the submandibular salivary glands. *International Journal of Oral and Maxillofacial Surgery.* 1986;15(6):769-71.
50. Kaltman S, Eichner M. Giant sialolithiasis appearing as odontogenic infection. *The Journal of the American Dental Association.* 1987;115(3):425-6.
51. Lakhoo K, Mannell A. Giant submandibular calculus. A case report. *South African Journal of Surgery Suid-Afrikaanse Tydskrif Vir Chirurgie.* 1989;27(5):187.
52. Tinsley G. An extraordinarily large asymptomatic submandibular salivary calculus. *British Dental Journal.* 1989;166(6):199.
53. Bamgbelu O. A giant submandibular sialolith: management and complications. *Dental Update.* 1989;16(9):399-400.
54. Asfar S, Steitiyeh M, Abdul-Amir R. Giant salivary calculi: An orocervical fistula caused by a submandibular gland calculus. *Canadian Journal of Surgery Canadien de Chirurgie.* 1989;32(4):295-6.
55. Hubar J, Guggenheimer J, Evan M. Megalith. *Oral Surgery, Oral Medicine, Oral Pathology.* 1990;70(2):245.
56. Martín FP, Alonso JT, Escapa JG, Capa F. Giant calculus of the submaxillary gland. *Acta Otorrinolaringologica Espanola.* 1990; 41(4):265-7.
57. Akin I, Esmer N. A submandibular sialolith of unusual size: A case report. *The Journal of Otolaryngology.* 1991;20(2):123-5.
58. Paul D, Chauhan S. Salivary megalith with a sialo-cutaneous and a sialo-oral fistula: A case report. *The Journal of Laryngology & Otology.* 1995;109(8):767-9.
59. Eiraku D Ae. A case of large intraductal sialolith. Abstract of 53rd Annual Meeting of Japanese Stomatological Society. 1999; NO. I-F-53
60. Bodner L. Giant salivary gland calculi: Diagnostic imaging and surgical management. *Oral Surgery, Oral Medicine, Oral Pathology, Oral Radiology and Endodontology.* 2002;94(3):320-3.
61. Siddiqui S. Sialolithiasis: An unusually large submandibular salivary stone. *British Dental Journal.* 2002;193(2):89.
62. Vittal U, Shetty SC, Manvikar P, Kini U, Gupta S. Giant sialolith (megalith) of submandibular salivary gland. *Australian Journal of Oto-Laryngology.* 2002;5(1):43.
63. Akimoto Y, Sakae T, Toyoda C, Ono M, Hasegawa K, Tanaka S, et al. An unusually large submandibular salivary calculus: Case report and structural analysis. *International Journal of Oral-Medical Sciences.* 2004;2(1):50-3.
64. Yildirim A. A case of giant sialolith of the submandibular salivary gland. *Ear, Nose and Throat Journal.* 2004;83(5):360-2.
65. Chan EK, Patel ND. Giant calculus of the submandibular salivary duct. *Ear, Nose and Throat Journal.* 2006;85(5):306-8.
66. Alkurt MT, Peker I. Unusually large submandibular sialoliths: Report of two cases. *European Journal of Dentistry.* 2009;3(2):135.
67. Patil S, Sharma S, Prasad LK. Submandibular megalith with erosion of the floor of mouth-A rare case report. *World Articles in Ear, Nose and Throat.* 2009;2.
68. Krishnan B, El Gehani R, Shehumi MI. Submandibular giant sialoliths—2 case reports and review of the literature. *Indian Journal of Otolaryngology and Head & Neck Surgery.* 2009;61(1):55-8.
69. Huang T, Dalton J, Monsour F, Savage N. Multiple, large sialoliths of the submandibular gland duct: a case report. *Australian Dental Journal.* 2009;54(1):61-5.
70. El Gehani R, Krishnan B, Shehoumi MI. Submandibular giant sialoliths: Report of two cases and review of the literature. *ENT: Ear, Nose & Throat Journal.* 2010; 89(6).
71. Khen AAB. An unusual large submandibular gland calculus: A case report. *Smile Dental Journal.* 2010;5:14-7.
72. Silva-Junior G, Picciani B, Andrade V, Ramos R, Cantisano M. Asymptomatic large sialolith of Wharton's duct: A case report. *international Journal of Stomatology & Occlusion Medicine.* 2010;3(4):208-10.
73. Lokesh Babu K, Jain MK. Giant submandibular sialolith: A case report and review of literature. *Int J Head and Neck Surg.* 2011;2(3):154-7.
74. Iqbal A, Gupta AK, Natu SS, Gupta AK. Unusually large sialolith of Wharton's duct. *Annals of Maxillofacial Surgery.* 2012;2(1): 70.
75. Rauso R, Gherardini G, Biondi P, Tartaro G, Colella G. A case of a giant submandibular gland calculus perforating the floor of the mouth. *ENT: Ear, Nose & Throat Journal.* 2012;91(6).

76. Tyagi S, Yadav S, Kumar P, Bhandari PP. Large intraductal sialolith in Wharton's duct. *SRM Journal of Research in Dental Sciences*. 2013;4(1):43.
77. Pandarakalam C, Goebel WM, Seyer B. Chronic sclerosing sialadenitis or Küttner's tumor associated with a giant sialolith: A case report. *Oral Surgery, Oral Medicine, Oral Pathology and Oral Radiology*. 2013; 115(4):e38-e40.
78. Singh S, Singh S. Submandibular gland megalith eroding the floor of the mouth: A case report. *ENT: Ear, Nose & Throat Journal*. 2013;92(12).
79. Banerjee K, Chattopadhyay S, Arora R, Banerjee SB. Surgical removal of a submandibular megalith. *BMJ Case Reports*; 2013.
80. Rodrigues GHC, Carvalho VJG, De Abreu Alves F, Lemos CA, Jaguar GC. Giant submandibular sialolith: Case report. *Oral Surgery, Oral Medicine, Oral Pathology and Oral Radiology*. 2014;117(2):e159.
81. Arslan S, Vuralkan E, Çobanoğlu B, Arslan A, Ural A. Giant sialolith of submandibular gland: Report of a case. *Journal of Surgical Case Reports*. 2015;4:rjv043.
82. Sari KSC. Giant submandibular gland duct sialolith: A case report. *Kafkas J Med Sci*. 2015;5:75-7.
83. Demircan S. Case reports: Giant sialolith. *British Dental Journal*. 2015;219(2):48.
84. Bhullar RS, Dhawan A, Bhullar K, Malhotra S. Giant submandibular gland duct sialolith mimicking an impacted canine tooth. *National Journal of Maxillofacial Surgery*. 2015;6(1):89-92.
85. Akinyamoju AO, Adisa AO. Non-surgical extraction of a massive sialolith in the Wharton's duct of a Nigerian. *African Journal of Medicine and Medical Sciences*. 2015;44(2):177-80.
86. Omezli MM, Ayranci F, Sadik E, Polat ME. Case report of giant sialolith (megalith) of the Wharton's duct. *Nigerian Journal of Clinical Practice*. 2016;19(3):414-7.
87. Gill DDR, Halpern L, Janet Southerland A. Giant submandibular sialolith in the setting of chronic sialadenitis: A case report and literature review. *Annals of Otolaryngology and Rhinology*; 2016.
88. Abdullah O, Alqudehy Z. Giant submandibular sialolith: A case report and literature review. *Indian Journal of Otolaryngology*. 2016;22(2):126-8.
89. Oliveira TP, Oliveira INF, Pinheiro ECP, Gomes RCF, Mainenti P. Giant sialolith of submandibular gland duct treated by excision and ductal repair: A case report. *Brazilian Journal of Otorhinolaryngology*. 2016;82(1):112-5.
90. Goh LC, Chitra BK, Shaariyah MM, Ng WSJ. Transcervical approach to the removal of a deep-seated giant submandibular calculus and the submandibular gland. *BMJ Case Reports*; 2016.
91. Siddika A, Ferdoushi AMZSS. Removal of unusually large torpedo sialolith from wharton's duct under local analgesia: A case report. *Mymensingh Medical Journal*. 2016;25(3):555-8.
92. Weinberg A, Albers AE. Giant sialolith after submandibulectomy. *Pan African Medical Journal*. 2016;25.
93. Lim EH, Nadarajah S, Mohamad I. Giant submandibular calculus eroding oral cavity mucosa. *Oman Medical Journal*. 2017; 32(5):432-5.
94. Iwai T, Izumi T, Ohya T, Oguri S, Tohnai I. Giant sialolith of the submandibular gland. *Journal of Clinical and Diagnostic Research*. 2017;11(8):ZJ03-ZJ4.
95. Sakthivel P, Yogal R, Singh S, Sharma P, Singh CA. Giant sialolith of submandibular duct. *Journal of the Nepal Medical Association*. 2017;56(206):262-4.
96. Rodrigues GHC, Carvalho VJG, Alves FA, Domaneschi C. Giant submandibular sialolith conservatively treated. *Autopsy & case reports*. 2017;7(1):9-11.
97. Mathew A, Cherian S, Daniel M. A Giant Sialolith in the Submandibular Salivary Gland Parenchyma - A Rare Entity. *J Ora Med*. 2018;2(1)1.

© 2019 Mostafavi Tabatabaee et al.; This is an Open Access article distributed under the terms of the Creative Commons Attribution License (<http://creativecommons.org/licenses/by/4.0>), which permits unrestricted use, distribution, and reproduction in any medium, provided the original work is properly cited.

Peer-review history:

*The peer review history for this paper can be accessed here:
<http://www.sdiarticle3.com/review-history/50988>*