

## **Treatment of Diabetic Foot Ulcer with Ointment Based on *Ceratothoa oestroides* Extract and Eosin- Case Report**

**E. Meimeti<sup>1</sup>, A. Psarou<sup>2</sup>, Ch. Loupa<sup>3</sup>, A. Vitsos<sup>1</sup>, N. Tentolouris<sup>4</sup>, V. Roussis<sup>5</sup>  
and M. Rallis<sup>1\*</sup>**

<sup>1</sup>Division of Pharmaceutical Technology, School of Health Sciences, National and Kapodistrian University of Athens, Panepistimiopolis Zografou, Athens, Greece.

<sup>2</sup>1<sup>st</sup> Internal Medicine Clinic, 401 General Military Hospital of Athens, Greece.

<sup>3</sup>Demetrios Voyatzoglou Diabetic Foot Clinic, A. Fleming Hospital, Athens, Greece.

<sup>4</sup>Diabetic Foot Clinic in General Hospital of Athens "Laiko", Athens, Greece.

<sup>5</sup>Division of Pharmacognosy and Chemistry of Natural Products, School of Health Sciences, Faculty of Pharmacy, National and Kapodistrian University of Athens, Panepistimiopolis Zografou, Athens, Greece.

### **Authors' contributions**

*This work was carried out in collaboration between all authors. Authors EM, MR and CL designed the study, wrote the protocol and first draft and final manuscript. Authors NT and AV participated to the design of the study, prepared the ointment, corrected the final draft. Author AP participated to the study protocol and with author EM followed the patient and took the necessary measures. Author VR advised and corrected the final manuscript, the parasite *Ceratothoa oestroides* came from his laboratory. All authors read and approved the final manuscript*

### **Article Information**

DOI: 10.9734/IJMPCR/2017/35531

Editor(s):

(1) S. Sundaresan, Department of Medical Research Centre, SRM Medical College, SRM University, India.

Reviewers:

(1) Murat Ugur, Health Sciences University, Sultan Abdulhamid SUAM, Istanbul, Turkey.

(2) Muhammad Shahzad Aslam, Universiti Malaysia Perlis, Malaysia.

(3) Giani Maria Cavalcante, Institute of Technology of Pernambuco, Brazil.

Complete Peer review History: <http://www.sciencedomain.org/review-history/20605>

**Case Study**

**Received 17<sup>th</sup> July 2017**  
**Accepted 16<sup>th</sup> August 2017**  
**Published 22<sup>nd</sup> August 2017**

### **ABSTRACT**

**Aim:** A case of a successful treatment using an ointment based on the olive oil extract of the isopod *Ceratothoa oestroides* and eosin sodium solution is described.

**Presentation of Case:** Obese woman with unregulated Type 2 Diabetes Mellitus, renal impairment

\*Corresponding author: E-mail: [rallis@pharm.uoa.gr](mailto:rallis@pharm.uoa.gr);

and smoker developed a severe infected wound in a previously amputated area of the right lower extremity. She was treated for 10 months by topical application of the isopod ointment, eosin solution and for the first four months clindamycin (600 mg) and ciprofloxacin (200 mg) was orally administered. The treatment was evaluated by measurement of the transepidermal water loss, skin hydration, photodocumentation and planimetry.

**Discussion:** Ten months after treatment, clinical evaluation, photo-documentation showed clearly that wound was almost healed. Wound area was reduced by 90%, transepidermal water loss by 36% and skin hydration was increased by 55%. These data seem very promising as the diabetic patient had damning characteristics concerning her health status in relation to wound healing process.

**Conclusion:** The combination of the *C. oestroides* ointment with the sodium eosin solution was effective in a grave case of diabetic foot ulcer. This significant healing effect should be further investigated.

**Keywords:** Diabetic foot; ulcer; *Ceratothoa oestroides* extract; inflammation.

## 1. INTRODUCTION

Diabetic foot is one of the most common and serious complications of diabetes, with a yearly incidence of approximately 2-4% in developed countries [1]. About 25% of patients with diabetes will develop diabetic foot ulcers (DFU) during their lives [2]. DFU are the major cause of patient suffering and economic costs. DFU may have a rapid development causing lower extremity amputation.

The pathophysiology of the "diabetic foot" includes infection, destruction of the deep tissue and ulceration associated with neurological disorders and various degrees of peripheral vascular disease at the extremities of persons with diabetes mellitus [3]. On the other hand, the pathophysiology of DFU healing comprises cytokines, chemokines, and growth factors produced mainly by platelets and macrophages [4]. In case of delayed treatment, a prolonged phase of inflammation takes place and a chronic FU is established.

The marine isopod *Ceratothoa oestroides* is a parasite found mainly in the oral cavity of sea bass and sea bream [5,6]. Olive oil extract of *C. oestroides* has a noticeable wound healing efficacy [7]. Compared to seventeen different preparations *C. oestroides* showed the most important wound healing activity without apparent toxicity in hairless mice wounds [8]. It is worth noting that *C. oestroides* even in second degree burns showed significant healing activity [9].

A case of DFU successful treatment of, using an ointment containing as active ingredient the olive oil *C. oestroides* extract, is described for the first time.

## 2. CASE REPORT

A 62-year-old obese (BM 42.52 kg/m<sup>2</sup>) female with unregulated Type 2 Diabetes Mellitus (T2DM) in the last 7 years, with renal impairment and smoker (40 packs per month), was referred to Diabetic Foot Clinic in General Hospital of Athens "Laiko" in March 2015. The patient presented with gangrene of the third and fourth toe of the right lower extremity. During hospitalization, she underwent amputation of the above mentioned toes.

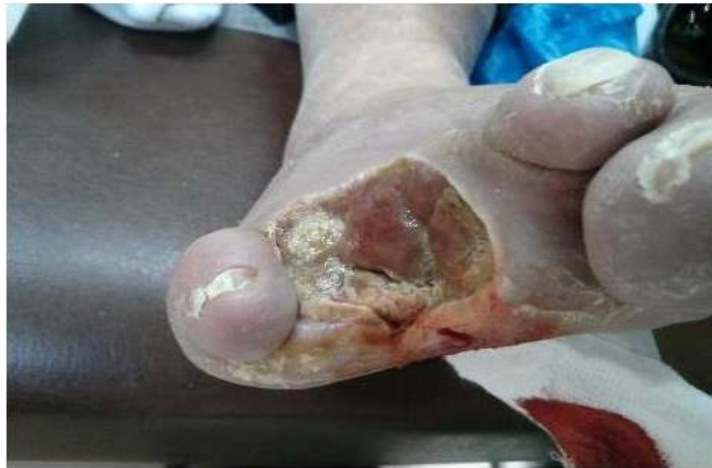Two months later, she developed a DFU in the amputation area. Upon clinical examination, she had an infected DFU (Fig. 1). Blood tests revealed high levels of inflammatory markers as Erythrocyte Sedimentation Rate (ESR)=60 mm/h, C-Reactive Protein (CRP)=16 mg/L (normal values:<3.14 mg/L). Ulcer cultures grew *Klebsiella oxytoca*. She was treated with oral clindamycin (600 mg three times daily) and ciprofloxacin (200 mg three times daily). Additionally, she was given instructions for offloading and prompted to quit smoking.

One month later, while receiving antibiotics, ulcer cultures were repeated and revealed *K. oxytoca* again. Therefore additional topical treatment with ointment was given to the patient, which was prepared in the laboratory of the Pharmaceutical Technology, unity of Cosmetology-Dermatopharmacology, of the National and Kapodistrian University of Athens. This was a novel product based on the oily extract of *C. oestroides*. Along with the administration of antibiotics, this new topical ointment was applied to the ulcer in combination with eosin as an antiseptic. The patient received the antibiotic treatment for a total of four months.

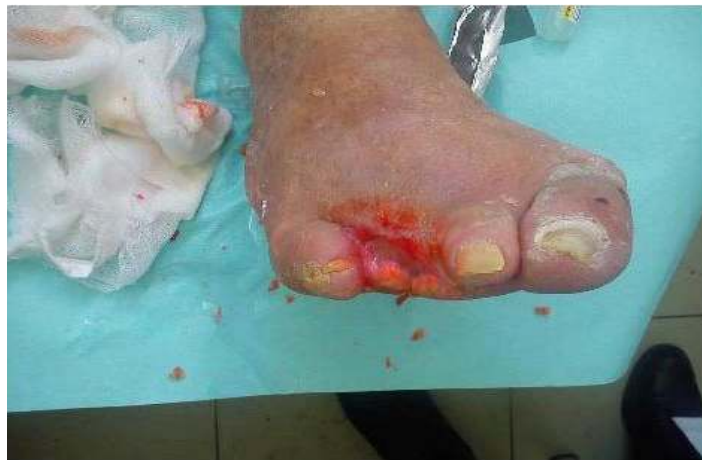One month after the initiation of local treatment, a significant improvement in inflammation indices was observed: ESR = 43 mm/h and CRP = 12 mg/L (normal values:<3.14 mg/L). Additionally, new cultures of the ulcer did not reveal any pathogen, neither during treatment nor at the end of treatment. The use of the isopod ointment and eosin reduced the extent of the ulcer as assessed in monthly follow-up visits (Figs. 2, 3).

In order to further evaluate and to objectively record the healing process it was examined the transepidermal water loss (TEWL) rate of the skin by the Tewameter TM 210 (Courage and Khazaka Electronic GmbH, Cologne, Germany), the level of skin hydration by a Corneometer CM 820 (Courage and Khazaka Electronic GmbH, Cologne, Germany) and the extent of the

DFU by photodocumentation (camera Sony Cyber-shot H300) measuring its dimensions using the image-analysis program AutoCAD (Autodesk Inc., San Rafael, California, U.S), at each monthly visit [10]. Tewameter TM 210 is a device which evaluates the skin water barrier function by measuring the humidity rate on the skin surface in  $g/h/m^2$  [11]. Furthermore, Corneometer CM 820 is a device that is used to accurately determine the level of hydration of the skin surface by measuring the electrical capacitance in arbitrary units [11]. During treatment the TEWL was reduced but the level of hydration was gradually increased in the skin of the FU (Fig. 4). The evolution of the wound area during the topical treatment is presented in Fig. 3. It is worth noting that the patient did not quit smoking and her BMI did not change during therapy.



**Fig. 1. Diabetic foot ulcer at baseline**



**Fig. 2. Diabetic foot ulcer after ten months of treatment with the isopod extract and eosin**

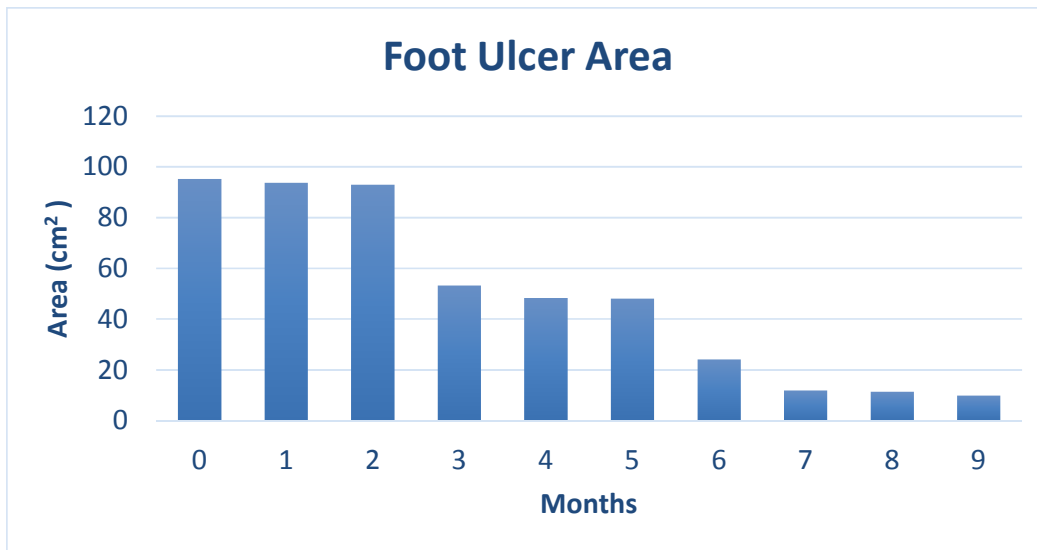


Fig. 3. Foot ulcer area evolution

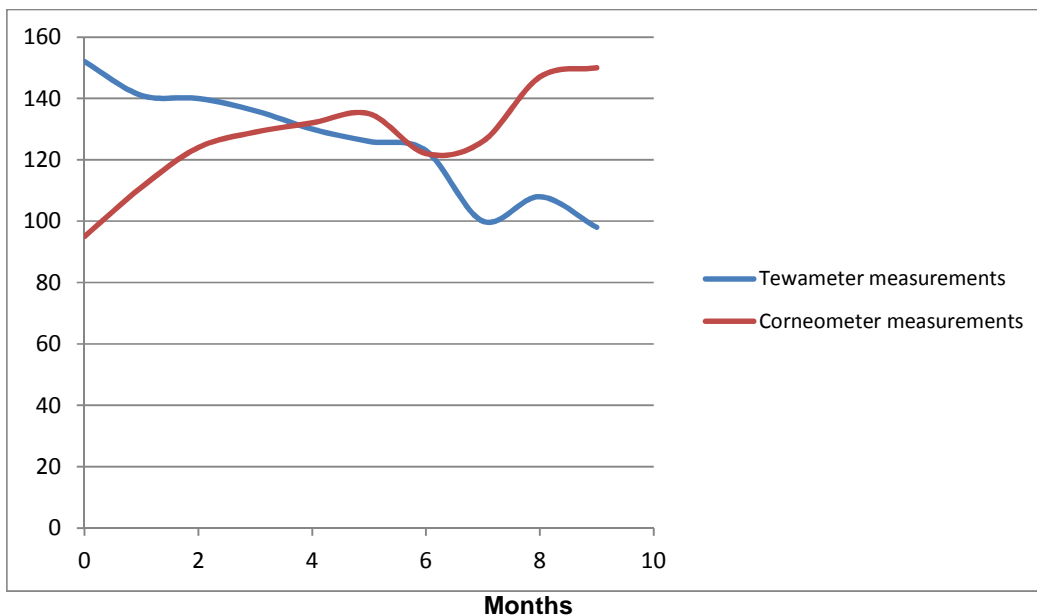


Fig. 4. Tewameter- Corneometer measurements at each patient's visit

### 3. DISCUSSION

It is well established that DFU consists a frequent complication of DM, influencing patient's quality of life and imposing an economic burden to the health system of developed countries [12,13]. A non infected ulcer is treated with dressings and offloading, while DF infections require additional antibiotic treatment. A number of alternative treatments have been tested, such as special

dressings, Vacuum Assisted Closure (VAC), growth factors, hyperbaric oxygen and fibroblasts/keratinocytes therapy [14-17]. All of these treatments having advantages and disadvantages, are only approved as additional therapies and are not included in the guidelines of the International Working Group on the Diabetic Foot [18]. Thus, treatment of DFU remains a serious problem and a great challenge for the scientific community.

The use of a *C. oestroides* extract in combination with eosin contributed significantly in the reduction of the ulcer. Ten months after treatment, clinical evaluation and photo-documentation showed clearly that wound was almost healed (Fig. 2). For the same treatment period wound area was reduced by 90%, from 95,31 to 9,96 cm<sup>2</sup>, TEWL by 36% from 152 to 98 g/h/m<sup>2</sup> and skin hydration was increased by 55%, from 95 to 150 A.U (Fig. 4).

The wound healing ability of *C. oestroides* ointment is considered very effective as the diabetic patient had high blood glucose levels, inflammatory markers were high when patient was received at the hospital (ESR=60 mm/h, CRP=16 mg/L), continued to smoke, had renal impairment and took for four months clindamycin, cirpofloxacin, parameters which are not favorable to healing process. Previous studies in hairless mice in our laboratory clearly showed that clindamycin hydrochloride applied topically in experimentally induced wounds delayed significantly wound healing process (unpublished data). The decrease of TWEL and increase of skin hydration during wound healing showed that skin barrier was significantly improved and so the quality of wound healing. TWEL is controlled by stratum corneum which constitutes the main barrier of the skin [19]. Its significant decrease by 36% showed a considerable barrier function improvement after treatment (Fig. 4).

As many parameters like gangrene amputation, serious infection, high glucose levels, renal impairment, antibiotic administration for a long period, tobacco smoke made the diabetic foot ulcer treatment much complicated. Its unexpected regeneration leave much hope that *C. oestroides* olive oil extract in combination to eosin solution could efficiently treat wound patients.

#### 4. CONCLUSION

Limb amputation was avoided and wound healing was achieved by topical administration of an ointment based on the oil extract of *C. oestroides* and a sodium eosin solution in a grave case of DFU.

The pre-clinical and clinical data are encouraging to intensify research on *C. oestroides* by further approaching its mechanism of action and confirming in a statistical manner up to date data.

*C. oestroides* olive oil extract in combination to eosin solution, facing up a so difficult case

should be a promising healing agent in the treatment of diabetic wounds.

#### CONSENT

The patient signed a consent form before receiving the novel treatment and she was informed about possible side effects.

#### ETHICAL APPROVAL

The study was conducted in accordance with the Helsinki Declaration. It was approved by the Scientific Committee of the General Hospital of Athens "Laiko" (314 / 02-04-2015), ensuring: legality of conduct, compliance with medical ethical standards, scientific validity.

#### COMPETING INTERESTS

Authors have declared that no competing interests exist.

#### REFERENCES

1. International working group on the Diabetic Foot. /Consultative Section of IDF 2007, Practical guidelines on the management and prevention of the diabetic foot - based on the International Consensus on the Diabetic Foot, Prepared by the International Working Group on the Diabetic Foot; 2007.
2. Singh N, Armstrong DG, Lipsky BA. Preventing foot ulcers in patients with diabetes. JAMA. 2005;293(2):217-28.
3. Foot WGotD. International consensus on the diabetic foot. Consultative Section of IDF; 2007.
4. Behm B, Babilas P, Landthaler M, Schreml S. Cytokines, chemokines and growth factors in wound healing. Journal of the European Academy of Dermatology and Venereology: JEADV. 2012;26(7):812-20.
5. Mladineo I. Life cycle of *Ceratohoa oestroides*, a cymothoid isopod parasite from sea bass *Dicentrarchus labrax* and sea bream *Sparus aurata*. Diseases of Aquatic Organisms. 2003;57(1-2):97-101.
6. Rameshkumar G, RS. Histopathological changes in the skins and gills of some marine fishes due to parasitic isopod infestation. Journal of Coastal Life Medicine. 2013;1(1):12-8.
7. Sofrona E, Charizani M, Kyriazi M, Sfiniadakis I, Ioannou E, Rallis M, Roussis V. Isolation structure elucidation and

- in vivo* wound healing evaluation of bioactive substances from the isopod *Ceratothoa oestroides*. 7<sup>th</sup> International Conference on Oxidative Stress in Skin Biology and Medicine; 2016. Andros, Greece
8. Rallis M, Koulourides I, Vitsos A, Deliconstantinos G, Vlachodimitropoulos D, Roussis V. Healing activity of different natural and chemical agents on experimental wounds. *Wound Repair and Regeneration*. 2012;20(5):A107.
  9. Daskalaki S, Liakos S, Fotopoulou K, Demertzis N, Kyriazi M, Roussis V, Vlachodimitropoulos D, Mourtzoukou H, Th. Papaioannou G, Kostomitsopoulos N, Rallis M. Treatment of second degree burn by traditional topical preparations. 6<sup>th</sup> International Conference on Oxidative Stress in Skin Biology and Medicine; 2014. Andros, Greece
  10. Chan B, Cadarette S, Wodchis W, Wong J, Mittmann N, Krahn M. Cost-of-illness studies in chronic ulcers: A systematic review. *Journal of Wound Care*. 2017; 26(Sup. 4):S4-S14.
  11. Mohd Noor N, Hussein SH. Transepidermal water loss in erythrodermic patients of various aetiologies. *Skin Research and Technology: Official Journal of International Society for Bioengineering and the Skin*. 2013;19(3):320-3.
  12. Constantin MM, Poenaru E, Poenaru C, Constantin T. Skin hydration assessment through modern non-invasive bioengineering technologies. *Maedica*. 2014;9(1):33-8.
  13. Kateel R, Augustine AJ, Ullal S, Prabhu S, Bhat R, Adhikari P. Development and validation of health related quality of life questionnaire (Indian scenario) in diabetic foot ulcer patients. *Diabetes & Metabolic Syndrome*; 2017.
  14. Adeghate J, Nurulain S, Tekes K, Feher E, Kalasz H, Adeghate E. Novel biological therapies for the treatment of diabetic foot ulcers. *Expert Opinion on Biological Therapy*. 2017;1-9.
  15. Health Quality O. Hyperbaric oxygen therapy for the treatment of diabetic foot ulcers: A health technology assessment. *Ontario Health Technology Assessment Series*. 2017;17(5):1-142.
  16. Munter KC, Meaume S, Augustin M, Senet P, Kerihuel JC. The reality of routine practice: A pooled data analysis on chronic wounds treated with TLC-NOSF wound dressings. *Journal of Wound Care*. 2017; 26(Sup. 2):S4-S15.
  17. Meimeti E, Donou A, Vogiatzoglou E, Vogiatzoglou D, Loupa Ch. Treating Diabetic foot ulcers using the system applying negative pressure. 24<sup>th</sup> Annual Meeting of the Diabetes Association of Northern Greece, Thessaloniki, Greece, 25-27 November; 2010.
  18. Bakker K, Apelqvist J, Lipsky BA, Van Netten JJ, International Working Group on the Diabetic F. The 2015 IWGDF guidance documents on prevention and management of foot problems in diabetes: development of an evidence-based global consensus. *Diabetes/metabolism research and reviews*. 2016;32(Suppl. 1):2-6.
  19. Antonov D, Schliemann S, Elsner P. Methods for the assessment of barrier function. *Curr Probl Dermatol*. 2016;49: 61-70.

© 2017 Meimeti et al.; This is an Open Access article distributed under the terms of the Creative Commons Attribution License (<http://creativecommons.org/licenses/by/4.0>), which permits unrestricted use, distribution, and reproduction in any medium, provided the original work is properly cited.

Peer-review history:  
The peer review history for this paper can be accessed here:  
<http://sciencedomain.org/review-history/20605>