



Revitalization of a Geminated Tooth with a Necrotic Pulp and an Open Apex Using Platelet-Rich Plasma (PRP) and Mineral Trioxide Aggregate (MTA): A Case Report

Gurmeet Singh Sachdeva¹, Munish Goel¹, Liza Thakur Sachdeva², Kulwant Rai¹
and Lisha Thakur^{1*}

¹Department of Conservative Dentistry and Endodontics, Himachal Dental College, Sundernagar, India.

²Department of Oral Pathology, Himachal Dental College, Sundernagar, India.

Authors' contributions

This work was carried out in collaboration between all authors. Author GSS designed the study, wrote the protocol and wrote the first draft of the manuscript. Other authors managed the literature searches, analyses of the study performed the spectroscopy analysis. All authors read and approved the final manuscript.

Article Information

DOI: 10.9734/BJMMR/2016/28987

Editor(s):

(1) Emad Tawfik Mahmoud Daif, Professor of Oral & Maxillofacial Surgery, Cairo University, Egypt.

Reviewers:

(1) Lauritano Dorina, University of Milan-Bicocca, Italy.

(2) Abu-Hussein Muhamad, Arab American University, Jenin, Palestine.

Complete Peer review History: <http://www.sciencedomain.org/review-history/16365>

Case Report

Received 16th August 2016
Accepted 19th September 2016
Published 28th September 2016

ABSTRACT

Aim: To successfully revascularize a geminated maxillary lateral incisor with an open apex using platelet-rich plasma (PRP) and mineral trioxide aggregate (MTA).

Methods: A 21-year-old male was referred for endodontic treatment of a geminated nonvital left maxillary lateral incisor (tooth #10) with asymptomatic apical periodontitis. After preparing an access cavity, its necrotic pulp was removed. The canal was irrigated with 5.25% NaOCl solution and dried with sterile paper points. A triple antibiotic mixed with distilled water was packed in the canal and left for 40 days. Ten ml of whole blood was drawn by venipuncture of the antecubital vein for preparation of PRP. After removal of the antibiotic mixture, the PRP was injected into the

*Corresponding author: E-mail: lishathakur12@gmail.com;

canal space up to the cemento-enamel junction level. Three millimeters of white MTA was placed directly over the PRP clot. Two days later, the tooth was double-sealed with permanent filling materials.

Results: Patient was recalled for 3, 6, 12 and 18 months clinical/radiographic follow up and is scheduled for a 24 months re-evaluation. Clinical examination, 12 months later revealed no sensitivity to percussion or palpation tests. Radiographic examination of this tooth showed appreciable regeneration of the root substance and resolution of the associated lesion. The tooth was not responsive to cold tests; however sensitivity test with an electric pulp tester (EPT) now elicited a delayed positive response.

Conclusions: On the basis of short-term results of the present case, it appears that PRP has the potential of an ideal scaffold for regeneration of vital tissues in teeth with necrotic pulp and a periapical lesion.

Keywords: Fusion; gemination; Mineral Trioxide Aggregate (MTA); Platelet-Rich Plasma (PRP); regenerative endodontic procedures; revitalization.

1. INTRODUCTION

Although millions of teeth are saved each year by root canal therapy, an ideal form of therapy might consist of a regenerative approach in which a diseased or necrotic pulp tissue is removed and replaced with a healthy pulp tissue to revitalize teeth. Regenerative endodontic procedures may be defined as biologically based procedures designed to replace damaged structures, including dentin and root structures, as well as cells of the pulp-dentin complex [1]. The objectives of regenerative endodontic procedures are to regenerate pulp-like tissue, ideally, the pulp-dentin complex, regenerate damaged coronal dentin, such as following a carious exposure and regenerate resorbed root, cervical or apical dentin [1].

Endodontic therapy in permanent teeth diagnosed with pulpal necrosis and immature root development is fraught with challenges. It is difficult to get an appropriate apical seal in teeth with open apices by using the conventional endodontic treatment methods. The discontinued development of dentinal walls after the pulp necrosis can also lead to a weak root structure with thin dentinal walls and poor crown-to-root ratio which makes the tooth susceptible to future fractures [2]. Traditionally, multiple-visit apexification with calcium hydroxide was the treatment of choice in necrotic immature teeth, which would induce formation of an apical hard tissue barrier [3]. Although this approach was predictable and successful [4], long-term use of calcium hydroxide has several disadvantages such as multiple treatment appointments, probable recontamination of the root canal system during treatment period and increased

brittleness of root dentin, which increases the risk of future cervical root fractures [4,5] and ankylosis. Recently, an alternative, biologically based, regenerative approach has been advocated on the basis of prior revascularization studies from the trauma literature [6,7]. The publication of several case series has led to growing recognition of the potential for successful outcomes by using regenerative procedures in treating the necrotic immature permanent tooth [8].

Hargreaves et al. [9] have identified three components contributing to the success of regenerative procedures. These include stem cells that are capable of hard tissue formation, signaling molecules for cellular stimulation, proliferation and differentiation and finally, a 3-dimensional physical scaffold that can support cell growth and differentiation. Platelet-rich plasma (PRP) has been mentioned as a potentially ideal scaffold for regenerative endodontic treatment regimens [9] in dentistry while platelet enriched plasma and fibrin glue is being used for conjunctival autograft in post pterygium surgery in ophthalmology [10].

This article describes successful revitalization of a geminated maxillary lateral incisor by using PRP as a 3-dimensional physical scaffold and MTA to create a hard tissue barrier and a probable source of signalling molecules for the growth of stem cells [11].

2. METHODS

A 21-year-old male patient was referred to the Department of Conservative Dentistry and Endodontics, Himachal Dental College,

Sundernagar (H.P.), India for endodontic treatment of tooth #10 (maxillary left lateral incisor). His medical history was non-contributory. The patient had experienced intermittent spontaneous pain in that area for previous months. Patient gave a history of trauma approximately 10 years earlier, wherein there was a direct impact on upper anteriors.

Clinical examination revealed an irregular unilateral morphology of tooth #10 (Fig. 1A), with an increase in the mesiodistal width suggestive of a possible union of two clinical crowns. The tooth was distolingually rotated. Distinct developmental occlusogingival grooves between the two clinical crowns were noticed (Fig. 1A, 1B). The rest maxillary and mandibular permanent teeth were evaluated by OPG (Fig. 1C) for any other anomaly and were found to be normal in shape and structure.

The tooth was tender on percussion. A draining sinus tract was also observed in relation to the involved tooth. No periodontal pockets were

present and thermal and electrical pulp testing elicited a negative response.

A periapical radiograph revealed that tooth #10 had two partially separated crowns with a single root and a single root canal (Fig. 2A). There was widening of the periodontal ligament space with periapical radiolucency in relation to the involved tooth. The sinus tract when traced by using a gutta-percha cone of size 20 (Dentsply Maillefer, Ballaigues, Switzerland) from the buccal aspect into the lesion pointed to tooth #10. On the basis of the clinical and radiographic findings (Fig. 2A), diagnosis of a “geminated nonvital tooth with symptomatic apical periodontitis” was made.

Considering various treatment options for tooth #10, a decision to perform a regenerative endodontic procedure with the aid of PRP was made. The patient was informed that this treatment was an attempt to initiate further root development and that the proposed treatment may not have a successful outcome. A written informed consent was obtained from the patient.

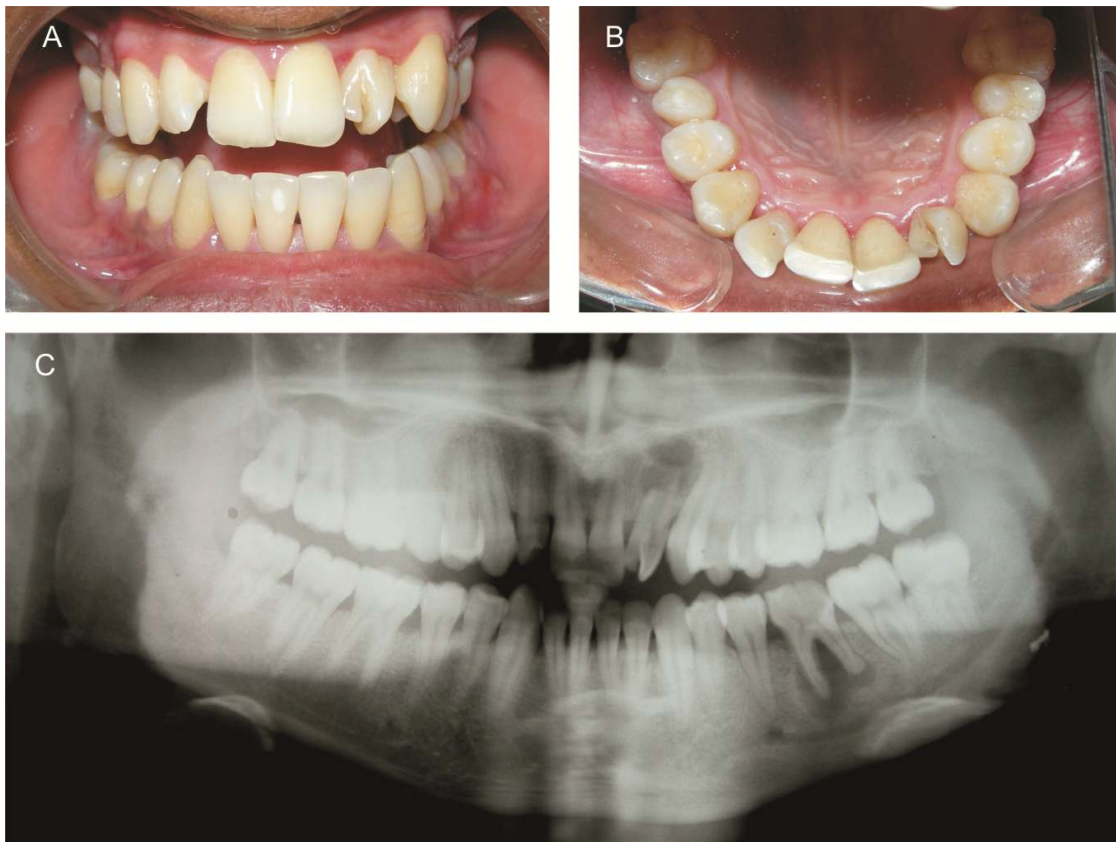

Fig. 1A and 1B. Preoperative photographs depicting unusual morphology of tooth #10
Fig. 1C. Orthopantomogram of the patient

After administration of local anaesthesia, that is, 2% lidocaine (Septodont, St Maur Des Fosses Cedex, France) with 1:80000 epinephrine, the tooth was isolated with rubber dam (Hygenic, Coltene/Whaledent, France) and cotton rolls. Endodontic access cavity (Fig. 2B) was prepared on the involved tooth using a diamond coated fissure bur (Diatech, Heerbrugg, Switzerland) in a high speed handpiece with copious water spray. No haemorrhage was observed from the root canal. The necrotic pulp was removed with the help of a barbed broach (Mani, Inc, Tochigi, Japan) and H-files (Mani, Inc, Tochigi, Japan) under copious irrigation with sterile saline 0.9% w/v (Alkem Laboratories Ltd., India). Coronal flaring was carried out with Gates Glidden drills (Mani, Inc, Tochigi, Japan) and working length was determined with the help of apex locator (Root ZX; Morita, Tokyo, Japan), which was later confirmed with a radiograph (Fig. 2C).

The root canal was irrigated with 5.25% sodium hypochlorite (Sigma-Aldrich Chemicals, Bangalore, India) copiously for 20 minutes without any instrumentation, followed by sterile saline 0.9% w/v (Alkem Laboratories Ltd., India). The root canal was then dried with sterile paper points (Dentsply, Maillefer, Baillaigues, Switzerland). Equal proportions of ciprofloxacin (Cifran, Ranbaxy, India), metronidazole (Metron, Ulticare-Alkem Laboratories, India) and minocycline (Divaine, Cipla, India) were ground and mixed with distilled water to a thick paste consistency. This antibiotic mixture was placed in the canal using a lentulo spiral (Mani, Inc, Tochigi, Japan). The access cavity was sealed with Cavit (3M ESPE AG, Seefeld, Germany) (Fig. 2D).

The patient returned to the endodontic clinic after 30 days and was without any symptoms. Tooth #10 was asymptomatic to both percussion and palpation tests. Local anesthesia was obtained by using 2% lidocaine with 1:80,000 epinephrine (Septodont, St Maur Des Fosses Cedex, France). After rubber dam (Hygenic, Coltene/Whaledent, France) isolation, the temporary restoration was removed and the antibiotic mixture was washed out by using sterile saline 0.9% w/v (Alkem Laboratories Ltd., India) irrigation. The canal was dried with sterile paper points (Dentsply, Maillefer, Baillaigues, Switzerland).

PRP was prepared by using the procedure as described by Okuda et al. [12] and Kawase et al. [12]. A 10 ml sample of whole blood was drawn

by venipuncture of the antecubital vein of the patient's right arm. Blood was collected in a 15-ml sterile glass tube coated with an anticoagulant (acid-citratadextrose, Health Line Pharmaceuticals Pvt. Ltd., India). Whole blood was initially centrifuged at 2,400 rpm for 10 minutes in a centrifuge (H.L. Scientific Industries, India) to separate PRP and platelet-poor plasma (PPP) portions from the red blood cell fraction. PRP and PPP portions were again centrifuged in a centrifuge (H.L. Scientific Industries, India) at 3,600 rpm for 15 minutes to separate the PRP from the PPP. PRP was then injected into the canal space up to the level of the cemento-enamel junction (CEJ). Three millimeters of white MTA (Pro-Root MTA; Dentsply Tulsa Dental Specialties, Tulsa, OK, USA) was placed directly over the PRP clot. A moist cotton pellet was placed over the MTA and provisionally restored with Cavit (3M ESPE AG, Seefeld, Germany).

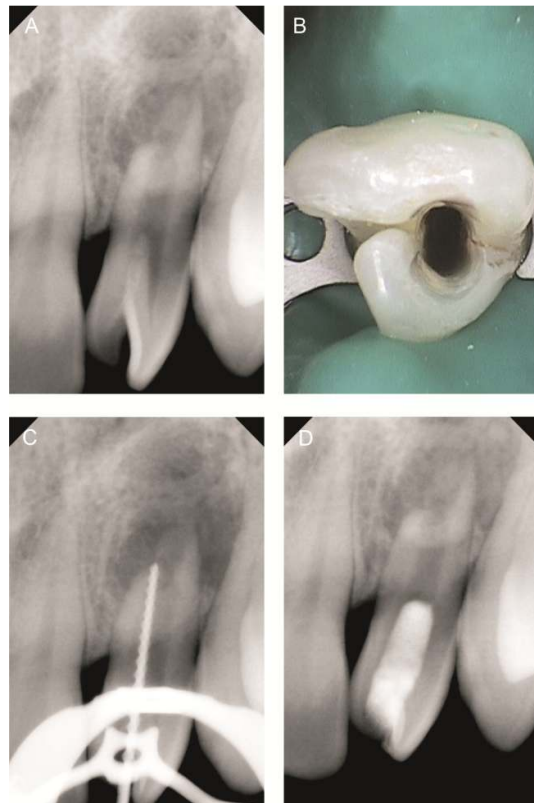


Fig. 2A. Preoperative radiograph of tooth#10
Fig. 2B. Access cavity preparation
Fig. 2C. Working length radiograph of tooth #10
Fig. 2D. Radiograph after PRP insertion and MTA placement

The patient was recalled after 2 days and was asymptomatic. After rubber dam (Hygenic, Coltene/Whaledent, France) application, the provisional restoration and cotton pellet was removed and setting of the MTA (Pro-Root MTA; Dentsply Tulsa Dental Specialties, Tulsa, OK, USA) was confirmed. The tooth was then double-sealed with 2 mm of glass ionomer cement (GC Corporation, Tokyo, Japan) and universal composite resin restorative material (3M ESPE Dental Products, St Paul, MN). The patient was recalled for 3, 6, 12 (Fig. 3A) and 18 months (Fig. 3B), clinical/radiographic follow up and is scheduled for a 24 months re-evaluation.

Clinical evaluation after 12 months revealed that the involved tooth was asymptomatic and was not sensitive to percussion or palpation tests. The tooth was not responsive to cold tests; however sensitivity test with an electric pulp tester (Parkell, Edgewood, NY, USA) now elicited a delayed positive response compared to the contralateral tooth. Radiographic examination showed resolution of the periapical lesion, further root development and continued apical closure of the root apex in tooth #10. The patient is now scheduled for a 24 months re-evaluation.

Fusion and gemination are developmental anomalies of dental hard tissues with complex and unusual anatomy. Gemination is considered as a result of a failed attempt of a tooth bud to split into two. The structure most often presents two crowns, either totally or partially separated,

with a single root and one root canal. It is characterized by a normal teeth number. An extra crown is usually present. The etiology is unknown, but trauma has been suggested as a possible cause, though a familial tendency has also been suggested [13]. Clinically, it is often difficult to differentiate between fusion and gemination and it is common to refer to these anomalies as “double teeth” [14]. The differential diagnosis between gemination and fusion of a normal and a supernumerary tooth is difficult. Traditional terminology such as fusion and gemination should be used as a potential embryologic cause of the anomaly and not as an exact diagnosis [15]. Concerning treatment, an exact differentiation between fusion and gemination may not be critically important [16].

Treatment of necrotic immature teeth has always been a challenge in endodontics. The primary objective of endodontic therapy in infected root canal systems is to disinfect the root canal system through chemical and mechanical means without injuring and irritating the periapical tissue. However, in teeth with immature root development, the removal of microorganisms by mechanical means is limited as a result of the thin, fragile dentinal walls of the roots. Disinfection of the root canal system in these cases often relies on irrigation and intracanal medicaments. All of this invariably injures the periapical tissue. After completion of traditional endodontic therapy, these teeth often have a poor crown-to-root ratio and are susceptible to fracture [17] or ankylosis.

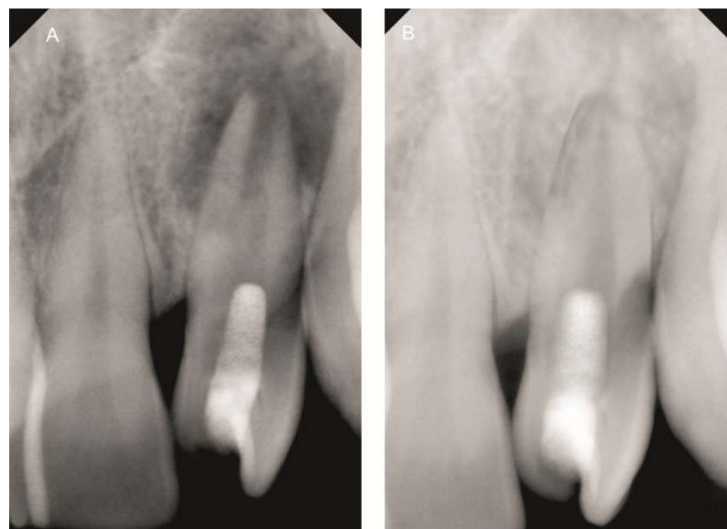


Fig. 3A, 3B. Postoperative radiographs after 3 and 12 months respectively

Traditionally, the treatment of immature permanent teeth with necrotic pulp involves long-term application of calcium hydroxide to induce apexification at the root apex [3]. However, the remaining thin fragile dentinal walls predispose these teeth to fracture and some studies have shown that long-term use of calcium hydroxide can weaken dentin [5]. An alternative technique for apexification with calcium hydroxide is an artificial apical barrier technique, which is done by placing barrier material in apical portion of the canal. The material of choice for this technique is mineral trioxide aggregate (MTA) [18], which has been shown to have high success rates [19] and reduce the number of required clinical sessions. Both of the mentioned methods (i.e. apexification and artificial apical barrier techniques) share the same disadvantage of not allowing the continuation of root development, which leads to a fragile root structure.

Revascularization is a regenerative treatment and a biologically based alternative approach to treat necrotic immature teeth that, unlike apexification and artificial apical barrier techniques, allows continuation of root development [20]. Regeneration of the pulp dentin complex had once been thought to be impossible. However, if a suitable environment could be achieved, i.e. absence of intracanal infection and presence of a scaffold conducive to tissue ingrowth, then regeneration of pulp may take place (and the pulpal space might become repopulated with mesenchymal tissue resembling the dental pulp [21]). Recently, the use of platelet-rich plasma (PRP) has been proposed as a method for increasing growth factor delivery. Compared to whole blood, PRP contains increased concentrations of platelets and, therefore, platelet-derived growth factors such as transforming growth factor β (TGF β 1), platelet-derived growth factors (PDGFs), and vascular endothelial growth factor (VEGF), which have been shown, *in vitro*, to promote cell migration, differentiation, and matrix synthesis. Although histologic studies are still lacking, the clinical outcome of these endodontic regeneration studies is promising. The publication of several case series has led to growing recognition of the potential for successful outcomes by using regenerative procedures in treating the necrotic immature permanent tooth.

The radiographic appearance of wide root canal systems and the presence of blunted roots strongly suggest a history of incomplete root development. Endodontic infection or physical

trauma of a developing tooth might lead to an unusual situation for root development [22]. 5.25% sodium hypochlorite was used as an intracanal irrigant as reported previously [23]. Triple antibiotics (a mixture of ciprofloxacin, metronidazole and minocycline paste) were used as an intracanal medicament to disinfect the root canal of this tooth as suggested by other investigators [23] and increase the chances of revascularization [24,25]. Tetracycline has been shown to enhance the growth of host cells on dentin via exposure of embedded collagen fibers or growth factors and not by an antimicrobial action [26]. Like many recent cases [23,27] MTA was placed over PRP to isolate the root canal from the external surface of the tooth and create a hard tissue barrier at its contact point with PRP. It might have also provided signaling molecules for the growth of stem cells [11].

3. CONCLUSION

In the presented case, resolution of the periapical lesion, further root development and continued apical closure of the root apex occurred within 6 months, which suggests the potential ability of PRP in regenerative endodontics. Histological backup regarding the nature of formed tissue(s) after this procedure in humans needs to be evaluated. However, pulp tissue, periodontal ligament, dentin, cementum and bone have been found within the root canals of teeth in experimental animals undergoing regenerative endodontic procedure [28].

On the basis of promising results of the present case, it appears that PRP is potentially an ideal scaffold for regeneration of vital tissues in a tooth with a necrotic pulp and periapical lesion. Further studies with long-term clinical follow-up and histological evaluation are recommended.

ETHICAL APPROVAL

It is not applicable.

COMPETING INTERESTS

Authors have declared that no competing interests exist.

REFERENCES

1. Murray PE, Garcia-Godoy F, Hargreaves KM. Regenerative endodontics: A review of current status and a call for action. *J Endod.* 2007;33:377-90.

2. Camp J, Fuks A. Pediatric endodontics: Endodontic treatment for the primary and young permanent dentition. In: Cohen S, Hargreaves K, Keiser K, eds. Pathways of the pulp. 9th ed. St Louis: Mosby Elsevier. 2006;822–82.
3. Rafter M. Apexification: A review. Dent Traumatol. 2005;21:1–8.
4. Sheehy E, Roberts G. Use of calcium hydroxide for apical barrier formation and healing in non-vital immature permanent teeth: A review. Br Dent J. 1997;183:241–6.
5. Andreasen JO, Farik B, Munksgaard E. Long-term calcium hydroxide as a root canal dressing may increase risk of root fracture. Dent Traumatol. 2002;18:134–7.
6. Cvek M, Cleaton-Jones P, Austin J, Lownie J, Kling M, Fatti P. Effect of topical application of doxycycline on pulp revascularization and periodontal healing in reimplanted monkey incisors. Endod Dent Traumatol. 1990;6:170–6.
7. Cvek M, Cleaton-Jones P, Austin J, Lownie J, Kling M, Fatti P. Pulp revascularization in reimplanted immature monkey incisors—predictability and the effect of antibiotic systemic prophylaxis. Endod Dent Traumatol. 1990;6:157–69.
8. Jung IY, Lee SJ, Hargreaves KM. Biologically based treatment of immature permanent teeth with pulpal necrosis: A case series. J Endod. 2008;34:876–87.
9. Hargreaves K, Geisler T, Henry M, Wang Y. Regeneration potential of the young permanent tooth: What does the future hold? J Endod. 2008;34:S51–6.
10. Harvey S, et al. Comparison of fibrin glue and sutures for attaching conjunctival autografts after pterygium excision Uy. Ophthalmology. 2010;112(4):667-671.
11. Torabinejad M, Parirokh M. Mineral trioxide aggregate: A comprehensive literature review: part II—leakage and biocompatibility investigations. J Endod. 2010;36:190–202.
12. Okuda K, Kawase T, Momose M, et al. Platelet-rich plasma contains high levels of platelet-derived growth factor and transforming growth factor- β and modulates the proliferation of periodontally related cells *in vitro*. J Periodontol. 2003;74:849-57.
13. Jarvinen S, Lehtinen L, Milen A. Epidemiologic study of joined primary teeth in Finnish children. Community Dent Oral Epidemiol. 1980;8:201–202.
14. Brook AH, Winter GB. Double teeth: A retrospective study of 'geminated' and 'fused' teeth in children. Br Dent J. 1970;129:123–30.
15. Calikshan MK. Traumatic gemination—triple tooth: Survey of the literature and report of a case. Endod Dent Traumatol. 1992;8:130–3.
16. Kim E, Jou YT. A supernumerary tooth fused to the facial surface of a maxillary permanent central incisor: Case report. J Endod. 2000;26:45–8.
17. Wilkinson KL, Beeson TJ, Kirkpatrick TC. Fracture resistance of simulated immature teeth filled with resilon, gutta-percha, or composite. J Endod. 2007;33:480–3.
18. Shabahang S, Torabinejad M, Boyne P, Abedi H, McMillan P. A comparative study of root-end induction using osteogenic protein-1, calcium hydroxide, and mineral trioxide aggregate in dogs. J Endod. 1999;25:1–5.
19. Witherspoon D, Small J, Regan J, Nunn M. Retrospective analysis of open apex teeth obturated with mineral trioxide aggregate. J Endod. 2008;34:1171–6.
20. Hargreaves K, Law A. Regenerative endodontics. In: Hargreaves K, Cohen S, eds. Pathways of the pulp. St Louis: Mosby Elsevier. 2011;602–19.
21. Thibodeau B, Teixeira F, Yamauchi M, et al. Pulp revascularization of immature dog teeth with apical periodontitis. J Endod. 2007;33:680–9.
22. Il-Young Jung, Eui-Seong Kim, Chan-Young Lee, Seung Jong Lee. Continued development of the root separated from the main root. J Endod. 2011;37:711–4.
23. Banchs F, Trope M. Revascularization of immature permanent teeth with apical periodontitis: New treatment protocol? J Endod. 2004;30:196–200.
24. Ritter AL, Ritter AV, Murrar V, Sigurdsson A. Trope M pulp revascularization of replanted immature dog teeth after treatment with minocycline and doxycycline assessed by laser Doppler flowmetry, radiography, and histology. Dent Traumatol. 2004;20:75–84.
25. Yanpiset K, Trope M. Pulp revascularization of replanted immature dog teeth after different treatment methods. Endod Dent Traumatol. 2000;16:211–7.
26. Terranova VP, Odziemiec C, Tweden KS, Spadone DP. Repopulation of dentin

- surfaces by periodontal ligament cells and endothelial cells effect of basic fibroblast growth factor. J Periodontol. 1989;60:293–301.
27. Chueh LH, Ho YC, Kuo TC, Lai WH, Chen YH, Chiang CP. Regenerative endodontic treatment for necrotic immature permanent teeth. J Endod. 2009;35:160–4.
28. Ham JW, Patterson SS, Mitchell DF. Induced apical closure of immature pulpless teeth in monkeys. Oral Surg Oral Med Oral Pathol. 1972;33:438–49.

© 2016 Sachdeva et al.; This is an Open Access article distributed under the terms of the Creative Commons Attribution License (<http://creativecommons.org/licenses/by/4.0>), which permits unrestricted use, distribution, and reproduction in any medium, provided the original work is properly cited.

Peer-review history:

The peer review history for this paper can be accessed here:
<http://sciencedomain.org/review-history/16365>